

# Unusual foreign body in the rectum

By Mohan Lal,  
State Surgeon,  
General Hospital, Penang.

## Introduction

Foreign bodies have been introduced into the rectum since ancient times. The variety of foreign bodies which have found their way into the rectum is hardly less remarkable than the ingenuity displayed in their removal. Thus, a turnip was delivered by the aid of obstetric forceps; a tumbler with the mouth looking downwards was removed by filling it with plaster of Paris. Malaya, a rubber-producing country has its share of foreign bodies, including one made from sheet rubber. I would like to report this case in more detail.

## Case report

Mr. X, a married man with 10 children and headmaster of a school was admitted to hospital complaining of pain and inability to pass urine following insertion of a self-made foreign body up his rectum. Since a month before admission, due to chronic constipation and rectal irritation the patient himself had frequently inserted a home rocket shaped object made of freshly processed rubber sheet. On 1 January 1965, the day of admission, this rocket-shaped mass went right up the rectum and he was unable to get it out again. Pain and retention of urine made him seek hospital treatment.

Clinical examination revealed that the bladder was distended up to the level of the umbilicus. The upper end of the foreign body was to the left of the umbilicus. On examination per rectum a foreign body was felt one inch up the anus, and this was seen on proctoscopy.

All attempts to remove the foreign body via the anus failed. At laparotomy an attempt to expel the foreign body via the abdominal route through the anus also failed. The foreign body was finally removed by incising the sigmoid colon. The colon was closed in the layers and the abdomen

closed without a drain. The post-operative recovery was smooth.

The foreign body shown in FIG. 1 and 2 was 8½ inches long, 4 inches in diameter and 11 inches in circumference. It weighed 1 lb. 8 oz.

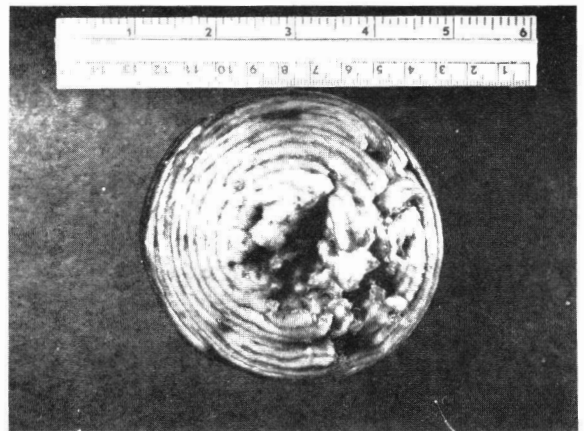


Fig. 1




Fig. 2

### Personal History

I was not able to obtain a detailed psychiatric history from the patient. It is difficult to believe that it was constipation and chronic irritation which had made the patient insert a self-made rocket-shaped mass into his rectum repeatedly. A more plausible explanation is that he was probably bisexual.

### Summary

An unusual foreign body in the rectum necessitating laparotomy for its removal is reported.

### Acknowledgement

I wish to thank Dr. Krishnappa, General Hospital, Johore Bahru, for taking the photographs and Datuk Dr. Majid the Director General of the Malaysian Medical Services for permission to publish this case report.

### Reference

BAILEY and LOVE, 'A Short Practice of Surgery,'  
14th Edition.