

# A Simple Technique of Intra-Uterine Transfusion of Foetus in University Hospital, Kuala Lumpur

by *Ng King Kwi*

Department of Radiology,  
University Hospital,  
Kuala Lumpur.

and *Ng Keng Hing*

Department of Obstetrics & Gynaecology,  
University of Malaya,  
Kuala Lumpur.

## Introduction

PRIOR TO the introduction of intra-uterine transfusion, severe Rhesus iso-immunization causes a very high foetal mortality of about 80% to 100%; however after its introduction by Liley in 1963, this procedure is now accepted as a standard for the management of severe Rhesus iso-immunization and the foetal salvage has improved considerably to between 35% to 50% (Whitfield 1972).

The purpose of this paper is to present a simple technique used in University Hospital, Kuala Lumpur for performing intra-uterine transfusion of the foetus.

## Selection of Patients:

Patients are selected for this procedure on the basis of spectrophotometric analysis of amniotic fluid. A placental scan is done first to localise the placenta. Amniocentesis is then performed. Spectrophotometric analysis of amniotic fluid is carried out. Patient is then selected for the intra-uterine transfusion of foetus only if the spectrophotometric analysis of amniotic fluid as outlined by Liley indicates that the foetus is severely affected. An additional indication is a history of previous foetal loss due to erythroblastosis.

## Preparation of Patient

A patient selected for the procedure is admitted on the day before the procedure is to be done. Laboratory studies on admission include complete blood count, repeat antibodies studies, and urinalysis. Amniocentesis is performed and 2 to 4 mls. of Myodil is injected into the amniotic cavity. On the morning

of transfusion, fresh Type O, Rh-negative blood is cross matched against mother's blood and the donor's blood is centrifuged to provide packed cells.

The patient is given 50 mgs. Pethidine and 50 mgs. Promethazine Hydrochloride intramuscularly one hour before the transfusion.

## X-Ray Equipment

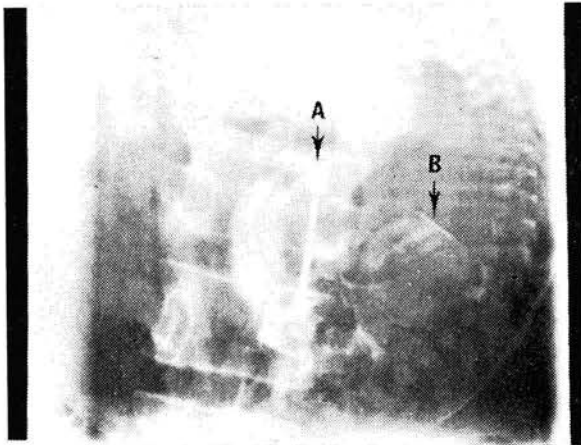
This includes an 'under-the-table' fluoroscopic tube and spot films tunnel supporting a 9" image intensifier, the out-put phosphor of which supplies the intensified fluoroscopic image to an orthicon television camera. The image is then displayed on to two television monitors so positioned that all participants in the procedure can have adequate viewing.

## Technique

The patient is placed supine on the x-ray table. Fluoroscopy is performed to determine the foetal positions. The Myodil introduced into the amniotic cavity the day before is adherent to the skin surface of foetus and outlines the foetus distinctly. Ideally the foetus should be lying in the position as the mother i.e. the foetal abdomen is directly anterior. However other positions can be acceptable as long as the operator can direct the needle into the amniotic sac, then into the foetal abdomen without encountering the placenta or any part of the baby other than the extremities. If the foetal abdomen is posterior with foetal spine upper-most, the procedure is best postponed until some change in foetal position can be induced or occurs spontaneously. The skin

area of the maternal abdomen which is directly opposite the centre of the foetal abdomen and through which the needle is to be inserted, is selected. The skin surface of the maternal abdomen is prepared and rendered sterile. A radiopaque metallic ring about 2" in diameter is placed on selected area of the maternal abdomen. The skin over the area selected is anaesthetized by local infiltration with Lignocaine. Under fluoroscopic control, an 18 cms. long 16 or 17 gauge Tuohy needle is directed into the foetal abdomen. There is a characteristic feel when it enters the foetal peritoneal cavity. 2 mls. of sterile saline solution is injected through the needle and if the saline can be introduced without any resistance, then 2 to 4 mls. of Urografin 30% is injected. A spot film is taken with an under-couch x-ray tube. One can ascertain that the contrast media has been placed in the peritoneal cavity by one or more of the following radiographic signs viz. Fig. I, Fig. II and Fig. III as shown.

with the catheters filled with contrast media, it gives a typical spring coil appearance. For the transfusion, fresh O Rh-negative packed cells are used. The blood is introduced gradually taking about 2 hours for the procedure. The amount of blood given is 60 mls. to 120 mls. depending on the foetal size and period of gestation. Foetal heart sound is periodically monitored during and at the conclusion of the procedure.

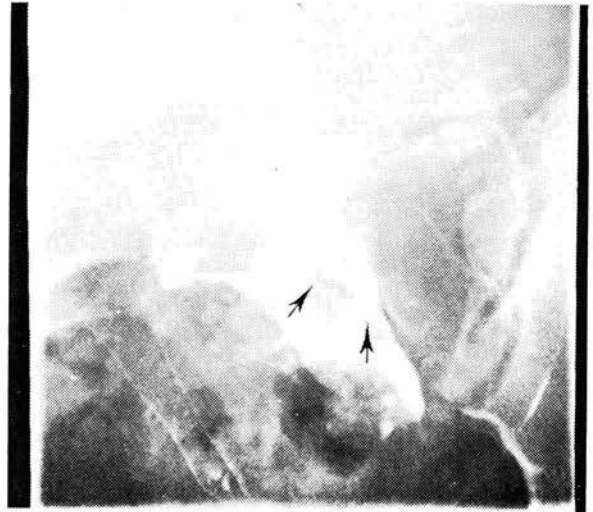


**Figure I.**  
Shows the Tuohy Needle (Arrow A) and outline of large bowel (Arrow B)

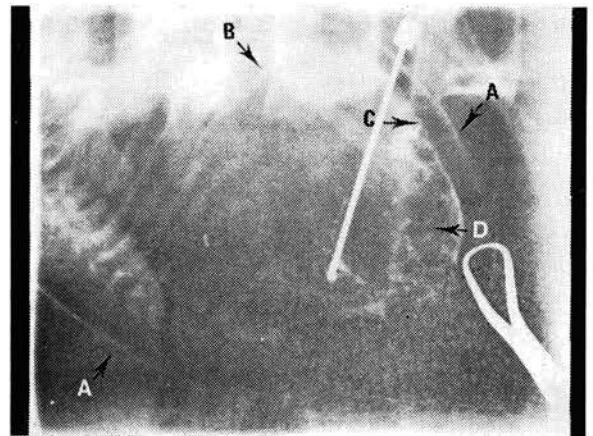
- (1) outline of the large bowel.
- (2) outline of under surface of the diaphragm.
- (3) outline of posterior surface of the abdominal wall.
- (4) collection of contrast media between loops of small bowel producing a typical 'honey-combed' appearance.

and (5) outline of the under surface of the liver.

A polyethylene catheter is then threaded into the peritoneal cavity through this needle and the needle is then withdrawn. A spot film is taken



**Figure II.**  
Shows collection of contrast media under the liver as indicated by the arrows.



**Figure III.**  
Shows the skin of foetal abdomen as outlined by Contrast media (Arrow A). Crescentic shape of contrast media under the Diaphragm (Arrow B). Outlines of posterior surface of anterior abdominal wall (Arrow C). 'Honeycombed' appearance (Arrow D).

Following completion of the transfusion, the maternal temperature, blood pressure, as well as the foetal heart rate are recorded every 4 hrs.

The intra-uterine transfusion is repeated at 2 to 3 weekly intervals until the 36th or 37th week of gestation when pregnancy is terminated.

#### Radiation Hazard to Foetus

With our existing obstetric-radiologic team, the radiological aspect of the procedure often takes about 30 mins. or less. With experience, one can further shorten the time of the procedure. The actual fluoroscopy is usually about 1 to 2 minutes duration, much of it done with a small field surrounding the needle tip and adjacent foetal land marks.

Beris et al (1972) found in intra-uterine transfusion that the average foetal dose was 617 m rads. to 1,117 m rads. They concluded that in view of the serious prognosis of erythroblastosis this amount of foetal radiation is acceptable.

#### Summary

- (1) The indications of intra-uterine transfusion are briefly discussed.
- (2) A simple technique of intra-uterine transfusion used in University Hospital, Kuala Lumpur is described.

and (3) Radiation hazards of the procedure to foetus are small. In view of the serious prognosis of erythroblastosis, the procedure justifies this small risk.

#### Acknowledgements

We wish to express our thanks to the Medical Illustration for the photography and Miss Florence Vendargon for typing the manuscript.

#### References

1. Fairweather, D.V. I., Tacchi, D., Coxon, A., Hughes, M. I., Murray, S. and Walker, W.: Intra-uterine transfusion in Rh-isoimmunization. *Brit. Med. J.*, 4: 189-194, 1967.
2. Liley, A. W.: Intra-uterine transfusion of fetus in haemolytic disease. *Brit. Med. J.*, 2: 1107-1109, 1963.
3. Liley, A. W.: The technique of fetal transfusion in the treatment of severe haemolytic disease. *Aust. N.Z.J. Obstet. Gynaecol.*, 4: 145-148, 1964.
4. Liley, A. W. The use of amniocentesis and fetal transfusion in erythroblastosis fetalis. *Pediatrics*, 35: 836-842, 1965.
5. Queenan, J. T.: Intrauterine transfusion: A cooperative study. *Am. J. Obstet. Gynaecol.*, 104: 397-405, 1969.
6. Whitfield, C. R., Thompson, W., Armstrong, M. J. and Reid, M. McC.: Intrauterine fetal transfusion for severe rhesus haemolytic disease. *J. Obstet. Gynaecol. Brit. Cwlth.* 79: 931-940, 1972.
7. Work, B., Jaffe, R. B., Campbell, C. and Whitehouse, W.: A technic of intra-uterine transfusion of the fetus. *Obstet. Gynaecol.*, 27: 319-322, 1966.
8. Bevis, D. C. A., Grech, Paul and Parsons, R. J.: Radiation hazard in intrauterine transfusion. *Br. J. Rad.*, 45: 193-196, 1972.