

Clinical application of ascending urethrography in males

by *Ng King Kwi*

MBBS (S'pore), DMRD (London)
Department of Radiology,
Faculty of Medicine,
University of Malaya,
Kuala Lumpur.

and

Yong Siew Leng

MBBS (Melbourne), FRACS
Department of Surgery,
Faculty of Medicine,
University of Malaya,
Kuala Lumpur.

ASCENDING URETHROGRAPHY is the retrograde examination of the male urethra. This can be done by three methods, viz:

1. Use of Knutsson clamp,
2. Use of Foley catheter, and
3. Use of a specially designed instrument.

Indications for urethrogram

Ascending urethrogram is done mostly in cases of urethral stricture. It is also done in cases of urethral injuries, urethro-perineal fistulae, urethral calculi and in demonstration of false passages following bougie dilatation of urethral stricture.

Contraindications

The examination is contraindicated in the presence of acute urethritis and balanitis.

Complications

- (1) The contrast medium may enter the cavernous tissue (urethrocavernous reflux) or blood vessels (intravasation). Hence, a water-soluble type of contrast medium is used to avoid the danger of pulmonary embolisation.
- (2) The danger of irradiation of testes must be evaluated against the advantages of the information obtainable. Lindholm and Romanns (1962), stated in the average examination the dose to the gonads amounts to 0.5 r per exposure.

Technique

We, in the Department of Radiology, Univer-

* Requests for reprints should be addressed to Dr. K. K. Ng.

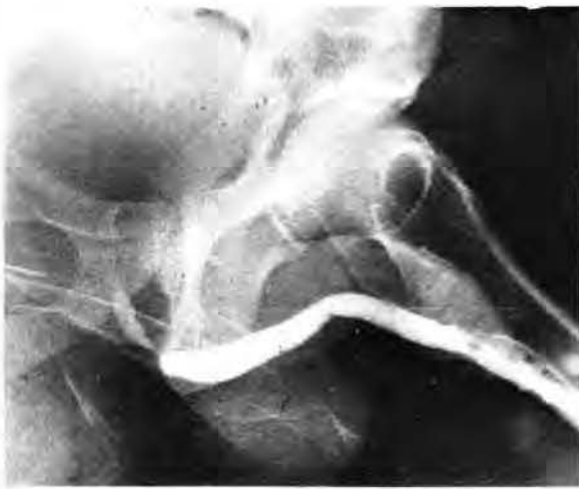CLINICAL APPLICATION OF ASCENDING URETHROGRAPHY IN MALES

sity Hospital, Kuala Lumpur, use a special instrument for ascending urethrography in males. (Ng, 1972).

Strict asepsis is essential. The patient is asked to empty his bladder before the start of the examination. A plain film of the pelvis is done. This may show the presence of:

- a. Prostatic calculi.
- b. Calcification in the bladder as seen in TB cystitis and Schistosomiasis.
- c. Urethral calculi.
- d. Sometimes even radio-opaque foreign bodies.

The patient is examined in the supine position. The instrument is properly applied and strapped onto the penis by a plastic strap. About 20 ccs. of Conray 280 is injected under fluoroscopic control. Spot films are then taken with patient in the AP, right oblique and left oblique positions. Sometimes spot films are taken with the patient in the true lateral position.

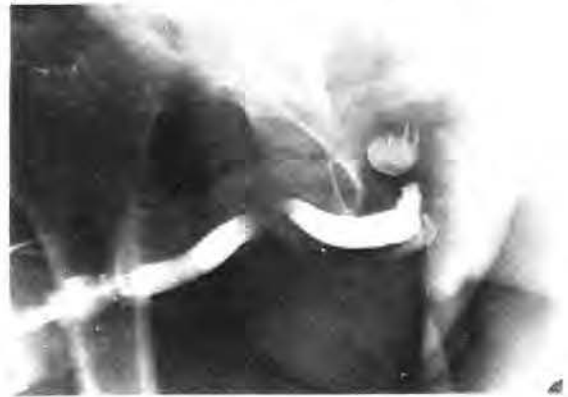

Radiological findings

I. Urethral stricture

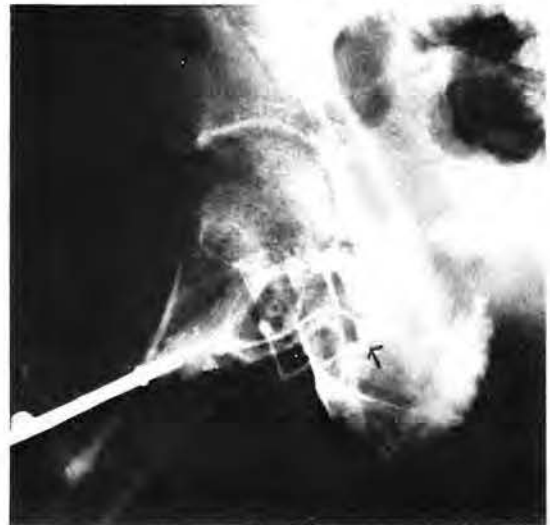
In all the ten cases examined, the urethral strictures were situated in the posterior urethra. The strictures were long in some cases and short in others. (see Figure I).

Figure I shows a short posterior urethral stricture in a 40-year-old Indian ambulance driver who complained of difficulty in micturition since 1968. He gave a history of exposure to venereal disease. Panendoscopy confirmed the presence of a stricture in the membranous urethra. Urethral dilatation was done, following which the patient voided well.



II. Urethral calculus

Figure II shows a stone situated within the posterior urethra of a 52-year-old Malay man who gave a history of hesitancy, poor-stream, frequency and bouts of dysuria, haematuria and overflow incontinence. No history of exposure to venereal disease was given. Prior to the urethrogram, urethral dilations were attempted but failed. The posterior urethral calculi were removed subsequently via a cystotomy. Urethral dilatation was done afterwards. Three months later, the patient was voiding well.



III. Urethro-perineal fistula

Figure III shows urethro-perineal fistula resulting from prolonged indwelling urethral catheterisation in a 19-year-old Indian man who developed quadri-plegia following a motor vehicle accident.

IV. Prostatic enlargement and false passage

Figure IV(a) and Figure IV(b) are films taken in ascending urethro-graphic examination of a 60-year-old Chinese man.

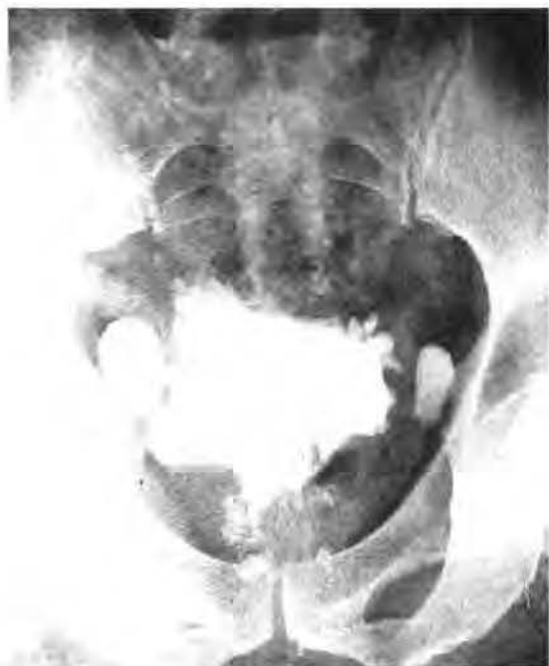

Figure IV(a) shows (1) Marked prostatic enlargement as evidenced by indentation at bladder neck and elongation of supra-collicular urethra as the enlargement of the prostate is proximal to the colliculus (Middlemiss 1952) and (2) Trabeculated and thick-walled bladder with bladder diverticula giving a "Mickey Mouse" appearance.

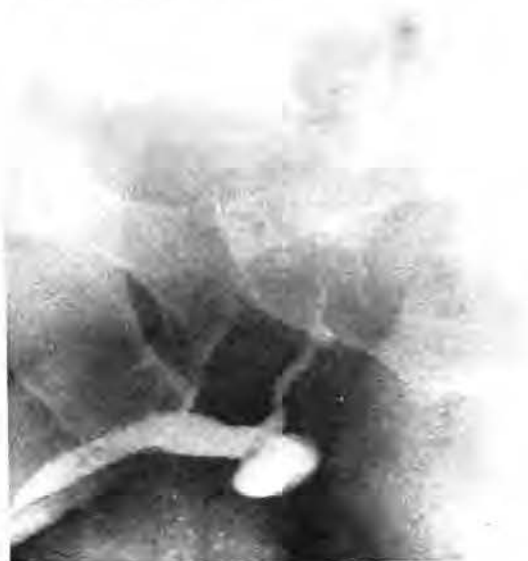

Figure IV(b) shows (1) A short stricture at the membranous urethra, and (2) A false passage with periurethral extravasation due presumably to previous dilatation. The patient gave a history of dysuria and urethral discharge nine years previously following contact with venereal disease. Six years ago, he had two episodes of acute retention of urine. Urethral dilatation was carried out at a district hospital on each occasion with relief of symptoms. He was admitted to the University Hospital with another acute episode of retention of urine. The above ascending urethrogram was done followed by dilatation of the urethra and trans-urethral resection of the prostate. The patient voided well after this.

Discussion

In the cases cited above, lesions in the male urethra were demonstrated by ascending urethrography.

The examination was technically simple to carry out. It was comfortable for the patient and was not attended by any untoward complication. However, the information which it provided was often valuable to the clinician.

In urethral stricture, the presence of long or multiple strictures would prepare the surgeon for a more difficult urethral dilatation. The sites of these strictures could also be clearly shown by the radiological examination, thereby making the urethral dilatation more safe for the patient.

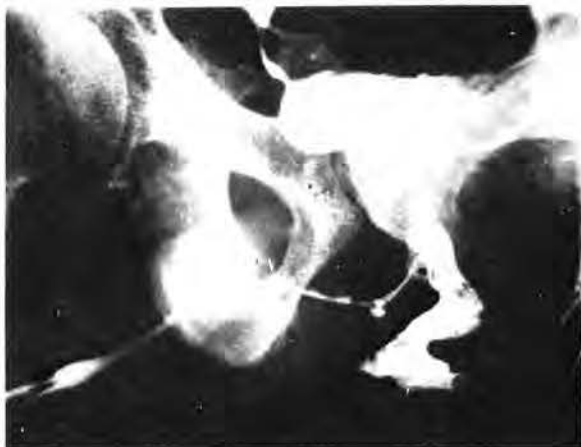The second case showed how easily a urethral calculus was missed, resulting in an unsuccessful and traumatic attempt at urethral dilatation. An ascending urethrogram performed before urethral dilatation would obviate the risk of urethral damage from "blind" urethral dilatation.

Case number three demonstrated a complication of prolonged urethral catheterisation.

The fourth case showed the value of ascending urethrography in demonstrating both lesions (namely, urethral stricture and prostatic enlargement) each of which could account for the patient's symptoms.

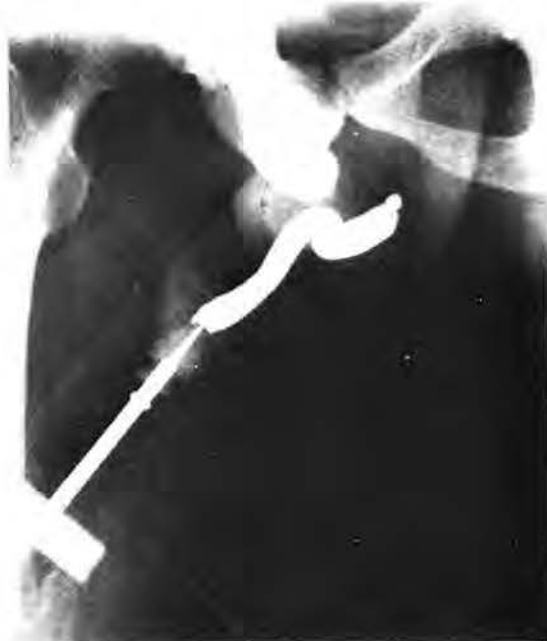In the absence of an urethrogram, one of these lesions could be missed. Dilatation of the urethral stricture without attending to the enlarged prostate would fail to relieve the patient's symptoms. Similarly, an unsuspected urethral stricture could make prostatectomy more difficult. Tuberculous urethritis is an unusual cause of urethral stricture. The fifth case, we believe, is such a case. The presence of tubercle bacilli in the urine and the typical radiological changes in the chest film and intravenous pyelogram are strong factors in favour of the diagnosis.

An ascending urethrogram may be very helpful in acute injuries of the urethra. The presence and



V. T.B. urethritis

Figure V. shows an irregularly narrowed urethra with urethro-perineal fistula and right vesico-ureteric reflux in a 53-year-old Chinese man. Chest X-ray showed changes consistent with pulmonary tuberculosis. Patient had an intravenous pyelogram which showed evidence of tuberculosis of the urinary tract, namely (a) a small contracted bladder; (b) ill-defined minor calyces of the right and left kidneys; and (c) strictures in the lower ends of both ureters with proximal dilatation. Clinical examination of patient revealed that the prostate was firm and irregular. The testes and epididymis were normal. Urine and sputum contained acid fast bacilli.



VI. Urethral injuries

Figure VI shows a total obstruction to the retrograde flow of contrast medium at the membranous urethra in a 38-year-old Indian labourer who was involved in a motor vehicle accident. The patient was unable to micturate. Urethral catheterisation failed and a suprapubic cystostomy was done. The above urethrogram was done one month after admission. About six months following the injury, the stricture of the membranous urethra was successfully dilated. With periodic dilatation, patient is able to micturate quite well.

site of urethral rupture are readily demonstrated. Treatment can then be decided upon.

In the sixth case, the urethrogram was done one month following injury. The delay in direct definitive treatment of the urethral rupture has made the subsequent management difficult. Moreover, the patient now required dilatations to keep his urethra patent. This may have been avoided if diagnosis and treatment was prompt.

Summary

Illustrative cases have been presented to demonstrate the clinical application of ascending urethrography in males.

Acknowledgement

We wish to thank Miss Florence Vendargon for

typing the manuscript and the members of the Department of Medical Illustration for the photographs.

References

1. Ng K.K. (1972) *Medical Journal of Malaya* No. 4, 291.
2. Middlemiss J.A. (1952) *Journal Fac. Radiol.* 4, 115
3. Uhle A.A. and McKinney W.H. (1931) *Urol Catan Rev.* 1, 27
4. Lindbolm K. and Romanus R. (1962): The encyclopedia of Urology. Volume 5/1. Diagnostic Radiology. ed., Atken C.E. Dix V., Weyrauch H.M. and Weldbolz (Berlin: Springer-Verlag).
5. "Medical Radiology" by David Sutton.
6. J.A. Veiga Pires, E.A. Flebate (1967) *British Journal of Urology.* 39;.....