

Hyperosmolar non-ketotic diabetic coma following Leptospirosis— A case report

by *Y. F. Chan*

BDS, MBBS

Medical Unit II,
Outram Road General Hospital,
Singapore

IN 1957, Sament and Schwartz gave the first clinical description of hyperosmolar non-ketotic diabetic coma, although Dreschfeld in 1881 reported two patients with diabetic coma which was not associated with dyspnoea or acetone in urine. Since then, this condition has been recognised more often with 32 cases reported by Danowski and Nabarro (1965) and no less than 63 cases reviewed by Schwartz and Apfelbaum (1966). The main features of this clinical syndrome are absence of ketosis, extreme hyperglycaemia, extreme dehydration and depression of sensorium (Johnson et al, 1969). This is an interesting case of a patient who apparently was admitted for leptospirosis but developed hyperosmolar non-ketotic diabetic coma and died of gram-negative septicaemia.

Clinical Record

H. bin H.L., a 70-year-old retired Malay cook, presented with fever, anorexia and yellowness of eyes of about ten days' duration. He was an old case of acute cholecystitis with cholecystectomy done in 1960. He was seen again in 1965 for epigastric pain, vomiting and passing of dark coloured urine and treated for cholangiohepatitis with a course of tetracyclines. Exploration of the common bile

duct was done later, but at operation it was noted that there was a fibrotic gall-bladder with a dilated common bile duct containing clear bile. There was also a large stone impacted in the common bile duct. Cholecystectomy was done again and post-operative recovery was good. He was apparently well until about one month prior to the present admission when he was admitted to the surgical unit for adhesion colic. He was treated conservatively and improved.

He never gave a history of diabetes mellitus but said that while working as a cook in the Police mess, he used to drink alcohol heavily (about $\frac{1}{4}$ to $\frac{1}{2}$ bottle of whisky a day).

Physical examination showed that the general condition was fair. He was febrile and the sclera was noted to be jaundiced. He had palmar erythema and spider naevi were present. He also had gross clubbing of the fingers. The blood pressure was 120/80 mm. Hg. and the liver was palpable, 1+ finger breadth. There was tenderness of the calves.

Investigations showed that there was no sugar in the urine and neither were there any bile or bile pigments. The total white count was 27,000/cu.mm. and liver function tests showed that the serum bilirubin was 4.5 mg.%, serum alkaline phosphatase 3.8 King-Armstrong units, serum glutamic-pyruvic

transaminase 300 King's units and albumin and globulin of 2.7 and 4.6 gm.% respectively. The sensitised erythrocyte lysis test (S.E.L.) was positive at 1/1600. A diagnosis of leptospirosis was made and the patient treated with capsules ampicillin 500 mg. 8-hourly. On the same night, he developed chills and rigors and by the next day had developed a temperature of 104°F. He was noted to be delirious. Blood culture was done and the patient given hydrocortisone 75 mg. 6-hourly. The condition, however, did not improve and the antibiotic was changed to injection cephaloridine 500 mg. 8-hourly.

As the patient was still delirious, it was decided to do a blood sugar. This was noted to be 1280 mg.%. The urine was re-tested and was noted to be brown. There was no acetone detected. The

osmolarity of blood was 368 while that of the urine 549 mOsm/L. Blood urea was 174 mg.% and serum potassium 2.4; sodium 130 and chloride 100 mEq./L.


A cannula was inserted into the basilic vein and the central venous pressure was monitored. Patient was given six pints half strength normal saline with 10 ml. 10% KCL in each pint. Soluble insulin was also given with the blood sugar coming down to 177 mg.%. The serum osmolarity came down to 326 the next day.

Meanwhile the condition of the patient improved and the blood culture results showed that *E. coli* was present. He was apparently well until the 30.10.70 when he suddenly collapsed and went into deep coma. There were coarse crepitations in the lungs and the blood pressure was still 120/70 mm. Hg. The blood sugar was 96 mg.% and blood urea 62 mg.%. The patient died without regaining consciousness half an hour later. A post-mortem lumbar puncture showed that it was heavily and evenly stained with blood. There was no post-mortem examination done because the patient was a Muslim.

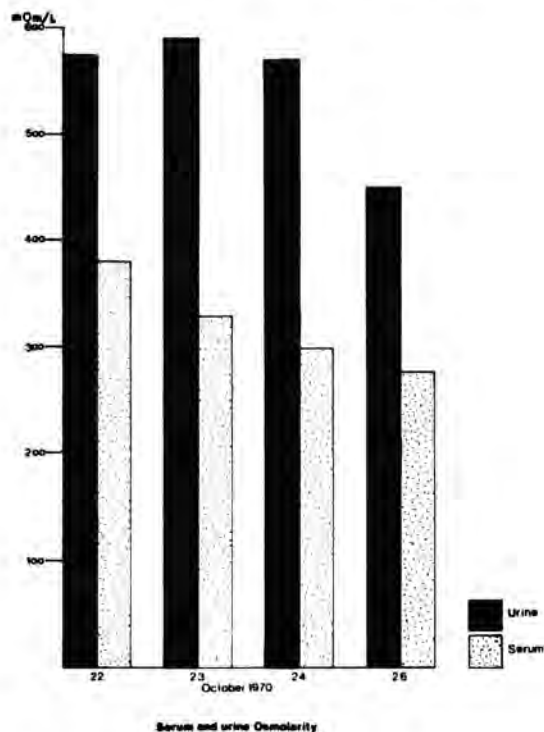
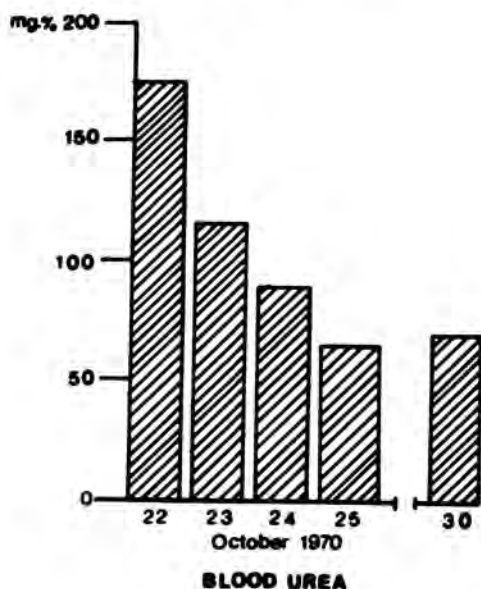
Discussion

Hyperosmolar coma is now increasingly recognised in clinical practice in Singapore. Two cases were reported by Tan, B.Y. et al. and four cases by Lim and Khoo in 1970. The aetiology is not altogether clear although the majority of cases reported in the literature were either mild or previously undiagnosed diabetics (Sheldon and Pyke, 1968; Halmos, Nelson and Lowry, 1966; Schwartz and Aptelbaum, 1965) and often there were also precipitating factors such as infection, stress, large ingestion of carbohydrates (Schwartz and Aptelbaum, 1965), peritoneal dialysis (Aust. Ann. Med., 1970, 3:263), haemodialysis (Potter, 1966), acute pancreatitis (Halmos, 1966), extensive burns (Ashworth et al 1968), steroid and immunosuppressive therapy (Spenny, Eure and Kreisberg, 1969) and dilantin administration (Johnson et al 1969). While Halmos et al. reported a case of septicaemia due to staphylococci, this patient died of *E. coli* septicaemia. However, it is not known whether the leptospirosis precipitated the hyperosmolar state or whether the hyperosmolar state was precipitated by the steroid administration during treatment. Infection was known to impair glucose tolerance and since the patient had clinical jaundice, liver impairment could have aggravated the hyperglycaemia.

According to Sheldon and Pyke (1968), hyperosmolar non-ketotic diabetic coma was seen more commonly in new diabetics. The age of onset



HYPEROSMOLAR NON-KETOTIC DIABETIC COMA FOLLOWING LEPTOSPIROSIS



of the patient was 71 although Sheldon and Pyke gave an average age of 62 years in their series of cases. Enrich and Bain (1967) reported the youngest patient with the condition at 1½ years.

Rossier et al 1961 gave results of hyperglycaemia of as high as 2,200 mg.% and also serum osmolarity of 458 mOsm/L. The patient's blood sugar was 1280 mg.% and serum osmolarity of 368 mOsm/L.

This patient was a known alcoholic and together with the previous history of cholangiohepatitis, his prognosis was not good. Schwartz and Apfelbaum (1965-1966) reported a mortality of 50%.

The therapy adopted by the Department of Clinical Medicine, University of Singapore is as follows:—

1. Early detection — this is only possible if one thinks about the condition.
2. Fluids — this is the mainstay of treatment and very rapid infusion of hypotonic saline solutions are made in order to combat hyperosmolarity. This may be supplemented by oral water if the patient can tolerate it. The usual practice is to do a central venous pressure monitoring if the patient has, in addition, developed shock. Half-strength normal saline is given I/V and orally or plain water via a Ryle's tube. As much as 10 to 20 litres may be given over 24 hours.
3. Insulin — soluble insulin is given but because of the absence of ketoacidosis, the

CHART SHOWING CLINICAL PROGRESS

| DATE | 1970 OCTOBER | 22 | 23 | 24 | 25 | 26 | 27 | 28 | 29 | 30 |
|-----------------------|--------------------|-------|--------|--------|--------|--------|--------|--------|--------|--------|
| CLINICAL STATE | PULSE | 120 | 120 | 78 | 90 | 120 | 110 | 90 | 100 | 110 |
| | BP | 90/50 | 100/60 | 120/60 | 150/70 | 120/70 | 140/70 | 110/70 | 110/70 | 110/70 |
| | CVP | 0 | 1 | 1 | 2 | | | | | |
| | STATE OF CONSCIOUS | C | C | C | C | C | C | C | C | U |
| INTAKE | TOTAL | 8330 | 8280 | | 8100 | 2940 | 2570 | 1340 | 1600 | |
| | I/V | 3430 | 3030 | | 2200 | 940 | 570 | 340 | 600 | |
| | ORAL | 2900 | 3250 | | 5900 | 2000 | 2000 | 1000 | 1000 | |
| OUTPUT | | 2585 | 1220 | | 2800 | 1700 | 590 | 1100 | 600 | |
| SOLUBLE INSULIN UNITS | | 60 | 36 | 44 | 24 | 60 | 46 | 46 | 16 | 16 |

response to insulin is very rapid. Moreover, there is also a significant amount of endogenous insulin present in patients as shown by Johnson et al (1969) whose second

case had a plasma immunoreactive insulin level of 29 uU/ml. at a blood sugar level of 720 mg.% and by Sheldon and Pyke (1968), whose second case also had a plasma insulin level of 40 uU/ml. at a blood sugar of 2500 mg.%. Therefore it is better to

start with smaller doses of soluble insulin than is required for keto-acidosis such as 20 units or less three to four times over 24 hours.

4. Electrolyte balance — with osmotic diuresis,

potassium is lost and correction is necessary.

5. Shock — if present, it is advisable to insert a central venous pressure catheter until clinical improvement occurs.

Acknowledgements

The writer is grateful to Dr. G. S. Lee who managed the patient, to Prof. O. T. Khoo for permission and encouragement to publish the case, to Messrs. C. W. Teo and K. P. Yap for the illustrations and to Mr. F. B. Vaz for secretarial help.

References

- Dreschfeld, J. (1881), "Diabetic Coma", *Brit. Med. J.*, 2, 358.
- Halmos, P. B. (1966), "Hyperosmolar Non-ketoacidotic Diabetic Coma in a Patient with Necrotising Pancreatitis", *Brit. Med. J.*, 2, 686.
- Johnson, R.D., Conn, J.W., Dykman, C.J., Pek, S. and Starr, J.L. (1969), "Mechanisms and Management of Hyperosmolar Coma without Ketoacidosis in the Diabetic". *Diabetes*, 18, 111.
- Lim, P. (1970), "Hyperosmolar State associated with Hyperglycaemia — Report of four cases". *Sing. Med. J.*, Vol. 11, No. 3, 152.
- Peretz, D.I. (1968), "Shock: Some Newer Concepts" Abbotempo, Book 2, 14.
- Potter, D.J. (1966), "Death as a Result of Hyperglycaemia Without Ketosis — a Complication of Hemodialysis". *Ann. Intern. Med.*, 64, 399.
- Sament, S. and Schwartz, M.B. (1957), "Severe Diabetic Stupor Without Ketosis". *South Afr. Med. J.*, 31, 893.
- Schwartz, T.B. and Apfelbaum, R.I. (1965-66), "Nonketotic Diabetic Coma". *Yearbook of Endocrinology (1965-66)*, p. 165 Chicago: Yearbook of Medical Publishers.
- Sheldon, J. and Pyke, D.A. (1968), "Severe Diabetic Ketosis Precoma and Coma", in "Clinical Diabetics and Its Biochemical Basis", edited by Oakley, W.G., Pyke, D.A. and Taylor, 1st Ed., 451. London; Blackwell Scientific Publications.
- Spenny, J.G., Eure, C.A. and Kresberg, R.A. (1969), "Hyperglycaemic, Hyperosmolar, Nonketoacidotic Diabetes — a Complication of Steroid and Immunosuppressive Therapy", *Diabetes*, 18, 107.
- Tan, B.Y., Cheah, J.S., Tan, S.K., and Chew, B.K. (1970), "Hyperosmolar Nonketotic Diabetic Coma". *Med. J. of Malaya*, Vol. 24, No. 4, 308.