

A triple-curve catheter for selective arteriography

THE TECHNIQUE of selective arterial catheterisation has been increasingly used in recent years, particularly since the advent of image-intensification with television monitoring and the availability of radio-opaque catheters have greatly simplified the procedure. Following the introduction of a suitably shaped catheter into the aorta, usually by the percutaneous trans-femoral route, the catheter tip may be manipulated under fluoroscopic control into almost any of the major branches of the abdominal or thoracic aorta. Subsequent injection of radio-opaque contrast material enables arteriograms to be obtained which are superior in quality and in diagnostic value to those achieved by aortography.

The factors responsible for the improved visualisation are:

- (1) The absence of overlying neighbouring branches of the aorta, particularly the abdominal aorta, which may obscure the area of interest; and
- (2) The absence of dilution which is inevitable with an aortic injection.

A further advantage is that with selective arteriography, much smaller volumes of contrast medium are required. The main setback of selective arteriography is that it is technically more difficult and time-consuming, with corresponding increase in fluoroscopic time, and consequently, radiation dose to both patient and operator. Any modification of technique that would simplify the procedure and shorten examination time is therefore most desirable.

Selective arteriography is often undertaken for the renal and coeliac axis arteries. The conventional catheter shape employed is one with a single curve centred about 1½ cm. from the tip, the angle of curve varying according to the patient, but usually in the

by *A.H. Ang*
and

J.T. Lambeth

Department of Radiology,
Faculty of Medicine,
University of Malaya,
Kuala Lumpur.

region of 60 degrees. Our recent experience with a triple-curve catheter suggests that it is an improvement on the conventional model, both reducing examination time and increasing the rate of successful catheterisation.

Preparation and Description of Catheter

We use the radio-opaque catheters designed by Odman (1956) and manufactured by Kifa of Stockholm. These can be rendered malleable by immersion in hot but not boiling water, bent to any desired shape, and then made rigid again by dipping into cold water. For selective coeliac axis and renal arteriography, we prefer the green Kifa catheter, which has an internal diameter of 1.20 mm. and an external diameter of 2.40 mm.

The shape of the catheter is as shown in Figure 1. The first curve is centred about 1½ cm. from the catheter tip, the second curve about 5 cm. from the centre of the first curve, and the third curve about 5 cm. from the centre of the second curve but in the opposite direction. The curves are such that they become more gradual the further away from the catheter tip, and that adjoining straight portions of

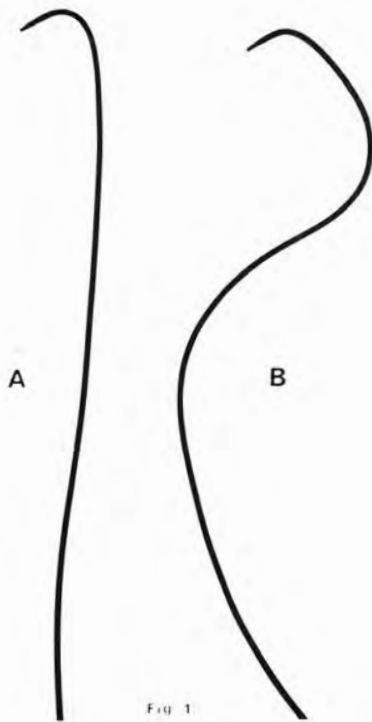


Fig. 1: A: Conventional single-curve catheter. B: Triple-curve catheter.

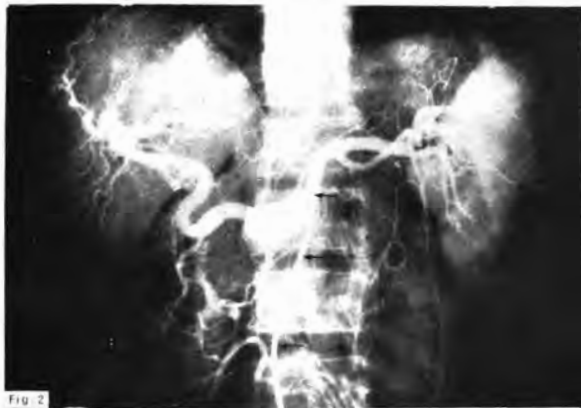

Fig. 2: Coeliac axis arteriogram performed for suspected hepatoma in a patient with cirrhosis. Arrows indicate the three curves of catheter.

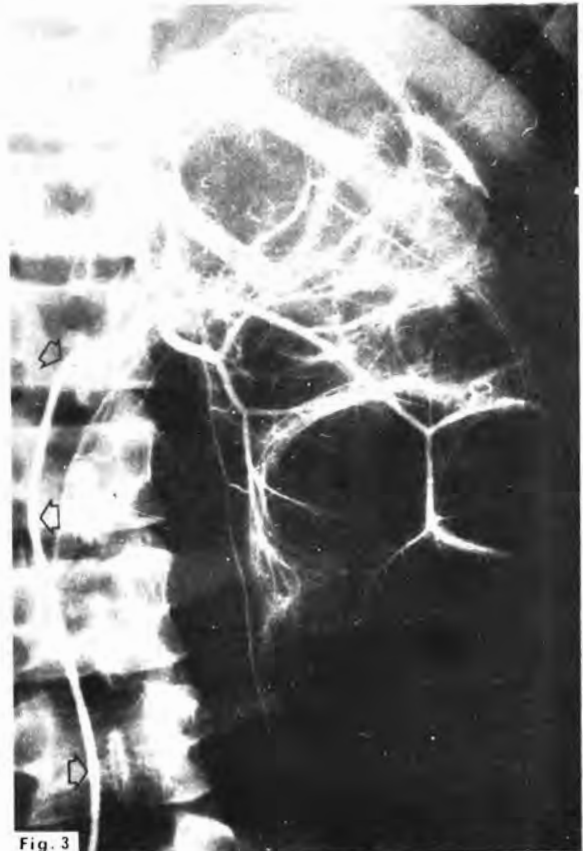

Fig. 3: Selective renal arteriogram in a patient with non-functioning hydronephrotic left kidney. Arrows indicate the three curves of catheter.

the catheter would intersect at an angle of 90 degrees if projected.

We have found this catheter shape to be equally suitable for both coeliac axis and renal artery catheterisation. (Figures 2 & 3)

Advantages of Triple-Curve Catheter

The two additional curves of the catheter not only facilitate flexion but, by providing two pivotal points of contact between the catheter and opposite walls of the aorta (Figure 4), allow for improved control and stability. In particular, we have noted the following advantages:

- (1) The curve at the catheter tip usually returns spontaneously upon withdrawal of the guide-wire. Should it fail to do so, the curve can be easily restored with a little manipulation.
- (2) Rotational movement of the catheter is

CATHETER FOR SELECTIVE ARTERIOGRAPHY

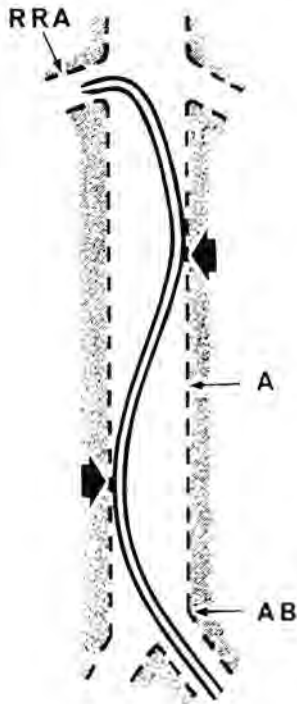


Fig. 4

Fig. 4: Diagram showing tip of catheter in right renal artery. RRA: right renal artery. A: Aorta. AB: Aortic bifurcation. Arrows indicate the two pivotal points of contact between catheter and aortic wall which permit improved control and stability.

much easier to control.

- (3) Once the desired artery has been entered, the catheter position is better maintained and the catheter is less liable to be dislodged by the recoil of injection. This applies particularly in the case of coeliac axis arteriography where higher injection pressures are used.
- (4) The catheter can be advanced deep into an artery and readily manoeuvred into one of its branches. In this way, it is possible to inject selectively the main branches of the renal artery.

Summary

- (1) A triple-curve catheter for selective coeliac axis and renal arteriography is described.
- (2) Its advantages over the conventional single-curve catheter are discussed.

Acknowledgements

We wish to thank the Department of Medical Illustration for the figures and Miss Janet Low for typing the manuscript.

References

1. Odman, P. (1956). Percutaneous Selective Angiography of Main Branches of the Aorta. *Acta Radiol.* (Stockholm), 45, 1.
2. Sutton, D. (1962). *Arteriography*, 33. Edinburgh & London: E. & S. Livingstone, Ltd.