

# Acute inversion of the uterus:

## A report of 2 cases and reappraisal of the method of management

ACUTE INVERSION of uterus is a very rare complication in modern obstetric practice. Das (1940) reported an incidence of one uterine inversion for every 14,881 deliveries, and Bell et al (1953) reported one in 4,894 deliveries. The maternal mortality rate has been quoted by different authorities to range between 15% and 70%.

Immediate recognition and treatment of the condition offers the best results. Proper management includes effective and early replacement of the inversion. Various methods of replacement of the inversion have been described namely, Johnson's manual replacement, O'Sullivan's hydrostatic method, and various operative procedures like Huntington's, Spinelli's and Kustner's operations. In this paper, two cases are described in which the Johnson's method of replacement of the uterine inversion was successfully used.

### CASE REPORTS:

**Case No. 1:** A 25-year-old Chinese housewife, gravida 3, para 2, had a full-term normal delivery in the University Hospital at 2025 hours on the 8th November, 1968. The baby weighed 2700 gm. (5 lb. 15 oz.) and the first and second stages lasted 5 hours and 25 minutes respectively. "Syntometrine" (1 ml.) was

by *Wong Wai Ping*

MBBS (S'pore) *and*

*T.A. Sinnathuray*

AM, MD (S'pore), BS (Malaya), FRCS (Edin.),  
FRCS (Glas.), MRCOG

(Department of Obstetrics and Gynaecology,  
University of Malaya Medical Centre,  
Kuala Lumpur)

given intramuscularly at crowning of the head. Controlled cord traction for delivery of the placenta was then commenced, after ascertaining that the uterus was well contracted. After half an hour of controlled cord traction, the patient began to complain of severe lower abdominal pain, not similar to labour pains. The placenta was partially delivered through the introitus at 2105 hours, and this was followed by severe post-partum haemorrhage. She then rapidly went into a state of shock.

Intravenous therapy was begun immediately — 1000 ml. of "haemacel" was given as quickly as possible. Attempts at manual removal of the placenta failed, and a careful vaginal examination revealed that the uterine fundus was inverted. She had, thus far,

lost 1000 ml. of blood and was still in a state of shock at 2145 hours. She was then given a general anaesthesia (atropine 1/100 gr.; d-tubocurarine 50 mg. + 40 mg.; and maintained with nitrous oxide and oxygen) and the inversion of the uterus was successfully and completely replaced, using Johnson's method.

No difficulty was encountered in the replacement. Following the replacement, she was given 0.5 mgm. ergometrine maleate intravenously; and 100 units of oxytocin in a pint of 5% of dextrose solution was given rapidly. Her general condition improved rapidly, after replacement of the uterine inversion. In all, she had transfusion of 2000 ml. of "haemacel" and 1350 ml. of blood.

The patient made a satisfactory recovery in the puerperium. She was treated for her anaemia (Hb = 8 Gm./100 ml.). She was seen for a post-natal checkup six weeks postpartum, and was found to be quite well.

**Case No. 2:** A 30-year-old Malay housewife, gravida 2, para 2, was admitted as an emergency case to the University Hospital at 1610 hours on the 6th April 1969, almost unconscious with a barely recordable blood pressure and pulse.

She had commenced labour spontaneously at 39th week of pregnancy on 5th April 1969, and was admitted to a general practitioner's maternity home about 2½ miles away from the University Hospital. Progress was satisfactory and she was considered to have completed her first stage at 1200 hours the next day (6th April). After a further 2 hours in the second stage, the general practitioner performed a forceps delivery. A big baby boy, weighing 4230 gm. (9 lb. 5 oz.) was delivered with some difficulty at 1435 hours.

"Syntometrine" 1 ml. was given intramuscularly after the delivery. The placenta was delivered by controlled cord traction after a further 25 minutes. It was claimed by the general practitioner to be "adherent at first, but came easily afterwards." This was followed by severe postpartum haemorrhage. The patient went into a state of shock immediately, and the following resuscitative measures were rapidly instituted by the general practitioner: 500 ml. of "haemacel" and 450 ml. of blood were given rapidly. An injection of "methidrone" (methyl-amphetamine HCl) 30 mgm. was given intramuscularly at 1510 hours. These measures brought her blood pressure up to the level of 90/60 mm.Hg. The blood loss was estimated by the general practitioner to be about 1500 ml.

She was then rushed to the University Hospital by

ambulance. On arrival, the patient was semi-conscious with "air hunger". The blood pressure was 80/60 mm.Hg., and the pulse rate was 120 beats per minute. The (apparent) uterine "fundus" (what appeared to be so) could be felt per abdomen. The uterine mass was assessed to be about the size of a 14-week gravid uterus and was "well-contracted". It was extremely tender. A vaginal examination revealed that the real fundus of the uterus had inverted into the vagina. The patient lost a further 1000 ml. of blood at the time of the present pelvic examination, most of which being blood clots from the distended vagina. She was immediately resuscitated by a rapid transfusion of 500 ml. of 5% dextrose, 500 ml. of "haemacel", and 450 ml. of blood. Her blood pressure was brought up to 90/60 mm.Hg. She was then given a general anaesthesia (methohexitone 50 mgm., suxamethonium 50 mgm. and oxygen) at 1720 hours.

The uterine inversion was successfully and completely replaced without much difficulty, again using the Johnson's method of manual replacement. Ergometrine maleate 0.5 mgm. was given intravenously and 50 units of oxytocin in a pint of 5% dextrose solution was given intravenously at a rapid rate to maintain the uterus in a firmly contracted state. The patient rapidly improved; her pulse rate was recorded at 120 beats per minute and her blood pressure at 100/60 mm.Hg., 15 minutes after the replacement. Multiple lacerations on the vaginal walls and a third degree perineal tear were repaired. The patient was estimated to have lost a further 300 ml. of blood during the procedure of replacement. A further transfusion of 1000 ml. of blood was given slowly.

She made an uneventful post-partum and post-operative recovery. Her haemoglobin level on the third post-partum day was eight gm. per 100 ml. She was given a course of imferon injections and folic acid tablets to correct her anaemia. At her post-natal visit four weeks post-partum, she complained of swelling of her right ankle for three days. She was found to have pitting oedema of the right leg for which no cause was detected, and this subsided two weeks later, when she was seen again.

## DISCUSSION

In the management of acute inversion of the uterus, the essential principles to be observed are as follows:-

- (1) Prevention of the occurrence of acute inversion of the uterus by the proper and skilful management of the third stage of labour. Acute inversion of the uterus is usually attributed to be the result

of "mismanagement of the third stage of labour", as may occur during the process of an improperly applied technique of "controlled cord traction" for the delivery of the placenta. Uncommonly, acute inversion of the uterus may be predisposed by pre-existent pathology in the uterus and placenta, such as placenta accreta. In both the cases described in this paper, no pre-existent pathological factor could be incriminated, and hence the resultant acute inversion of uterus can only be attributed to "mismanagement of the third stage of labour". The administration of oxytocics (ergo-metrine maleate or "syntometrine") prior to the performance of "controlled cord traction" will considerably minimise the risk of acute inversion of the uterus.

- (2) The early diagnosis and the prompt replacement of the inverted uterus will considerably reduce maternal morbidity and prevent maternal mortality. The presenting features in these two cases were the sudden severe post-partum haemorrhage and shock. In both cases, a "mass" could still be felt per abdomen, simulating a well contracted uterine fundus. Severe abdominal pain, especially following controlled cord traction, is an important symptom. An early vaginal examination in all cases of post-partum haemorrhage and retained placenta should always be indicated. Hurred infusion of oxytocics without a definite diagnosis can lead to tightening of the cervical ring, preventing easy replacement of the inverted uterus.
- (3) Prompt and effective resuscitation of shocked and exsanguinated patient should be carried out and maintained before, during and after the replacement of the inverted uterus. Rapid recovery is always associated with early replacement of the inverted uterus.
- (4) Strict asepsis should be observed during the procedure of replacement of the inverted uterus.
- (5) Good general anaesthesia is required to effect deep analgesia and adequate relaxation of the "ring" at the neck of the inverted uterus.
- (6) Skilful technique of replacement of the inverted uterus should be practised.

The method used in these two cases was the Johnson's method of manual replacement. There was no difficulty encountered. The procedure consisted of placing the entire hand in the vagina with the tips of the fingers at the utero-cervical junction and the fundus of the inverted uterus in the palm of the hand. The uterus was then lifted

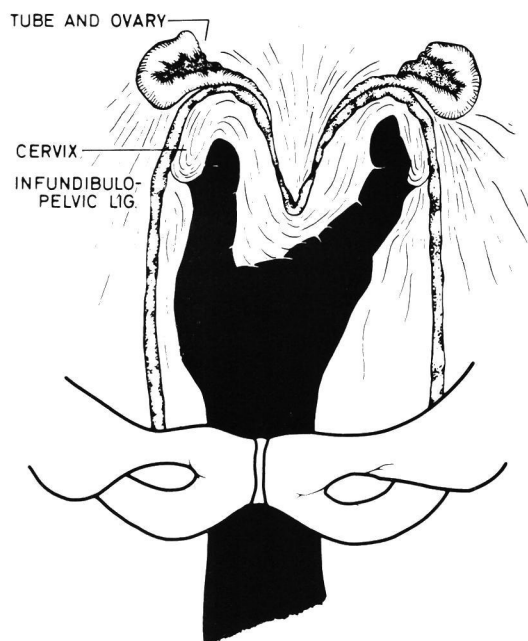


Fig. 1: Diagram showing the technique of application of Johnson's Method.

out of the pelvis and forcefully held in the abdominal cavity above the level of the umbilicus for three to five minutes. During this time, the fundus receded from the palm of the hand. To perform this procedure, it usually meant that the entire hand and two-thirds of the forearm must be placed in the vagina and the uterus. The basis of this method is the increased tension of the round, Mackenrodt, utero-sacral and pubo-cervical ligaments produced by lifting the uterus out of the pelvis. The ligaments are so situated that when they are placed under tension, pressure is exerted firstly to widen the cervical "ring" and secondly to pull the fundus through it, thereby replacing the uterus to the normal position.

- (7) The administration of potent oxytocics (ergo-metrine maleate and intravenous oxytocin drip 50 – 100 units per 500 ml. of 5% dextrose), after replacement of the inverted uterus to minimise further haemorrhage, is essential.

#### SUMMARY

1. Two cases of acute inversion of the uterus that were personally managed at the University Hospi-

## ACUTE INVERSION OF UTERUS

tal, Kuala Lumpur, are described.

2. Salient principles in the management of acute inversion of the uterus are discussed.
3. The Johnson's method of manual replacement of inversion of the uterus, which was successfully used in the management of these two cases, is described and discussed.

### ACKNOWLEDGEMENT

The Department of Medical Illustration, Faculty of Medicine, University of Malaya for the diagram of the Johnson's method.

### References

1. Bell, J.E., Jr., Wilson, G.F. and Wilson, L.A. (1953): Puerperal Inversion of Uterus. *Am. J. Obstet. & Gynaec.* 66:767.
2. Das, P., (1940): Inversion of Uterus. *J. Obstet. & Gynaec. British Empire* 47:525.
3. Donald, I. (1969): Practical Obstetric Problems 4th Edition Lloyd-Luke Ltd. P. 731 – 737.
4. Greenhill, J.P. (1969): Greenhill's Obstetrics 12th Edition W.B. Saunders & Co. P. 809 – 815.
5. Johnson, A.B. (1949): A new concept in the replacement of the Inverted Uterus and a report of 9 cases. *Am. J. Obstet. & Gynaec.* 57:557.
6. O'Sullivan, J.V. (1945): Acute Inversion of Uterus. *Brit. M. J.* 2:282.