

Meigs' syndrome:

A case report and review of the literature

MEIGS' SYNDROME is a very uncommon condition. In 1954, Meigs himself in a survey of the literature found 84 cases.⁹ Up to 1967, only a total of 129 cases were reported (Hammouda).⁵ As far as the writer is aware, this case presentation is the first Meigs' syndrome to be reported from Malaysia.

Interest in Meigs' syndrome is mostly focussed on the theories concerning the production of ascites and hydrothorax. What is not so commonly known is that, in recent years, there has been included in this syndrome a group of confusing cases which do not fall strictly within its scope.

All clinicians ought to be aware of this syndrome, for it can be mistaken for an inoperable malignant neoplasm of the abdomen and pelvis, though in fact it is completely curable.

Case Report

The patient, a Chinese woman aged 66 years, gravida 1, para 1, was first seen on 23.3.69 with the complaint of progressive enlargement of the abdomen of eight years' duration. For the past year, she also experienced lower abdominal discomfort and exertional dyspnoea. There was no urinary or bowel disturbances. The appetite was normal. Menopause occurred at 46 years of age.

Physical examination showed a thin elderly woman with no evidence of dyspnoea. The heart did not appear enlarged; the heart sounds were normal and no murmurs were heard. The blood pressure was 180/100 mm Hg. The chest showed dullness and reduced breath sounds in the right lung base. The abdomen was considerably enlarged by a solid, mobile mass which appeared to arise from within the pelvis. The liver, spleen, and kidneys were not palpable.

On pelvic examination, a hard mass was easily felt in the Pouch of Douglas. The atrophic uterus was pushed anteriorly.

by *Chan Wing Fook*

MBBS (Malaya), FRCS (Edin.), MRCOG
Lecturer in Obstetrics and Gynaecology,
University of Malaya,
Kuala Lumpur

Chest X-ray confirmed the presence of an effusion in the right lung base. An intravenous pyelogram revealed good renal function bilaterally. The bladder was displaced downwards and to the left by the tumour.

The haemoglobin level was 12.7 gm/100 ml; ESR 14 mm per hour; blood urea 34 mgm/100 ml. The ECG was normal. Vaginal cytology showed no tumour cells.

A laparotomy was done on 28.3.69, five days after admission. The right ovary was found to be enlarged by a solid lobulated mass, weighing 3380 grams and measuring 29 cm x 28 cm x 14 cm. There were numerous thin-walled cysts on the tumour surface. 450 ml of straw-coloured ascitic fluid were aspirated. The atrophic uterus, Fallopian tubes and left ovary were normal. A total hysterectomy and bilateral salpingo-oophorectomy were performed.

The postoperative recovery was uneventful, and the patient was discharged on the 12th day. A chest X-ray, repeated six weeks after operation, showed a complete resolution of the right pleural effusion.

Histological examination of the tumour confirmed the diagnosis of ovarian fibroma with no evidence of malignancy. The microscopic picture consisted mainly of well-differentiated bundles of collagenous tissue.

Discussion

Cullingworth⁹ (1878) was the first to publish a report of a case of ovarian fibroma with ascites and

MEIGS' SYNDROME

hydrothorax found at autopsy. Though in 1877, Demons⁸ in France reported a series of similar cases, it was not until 1937 that Meigs⁸ and Cass drew our attention to the importance of this condition. Lately, the concept of Meigs' syndrome has become distorted by the inclusion of certain other pelvic lesions under its name.^{1,2,13} Broadly, Meigs' syndrome may be classified as follows:

(1) True Meigs' syndrome

As stated by Meigs,¹⁰ this should be limited only

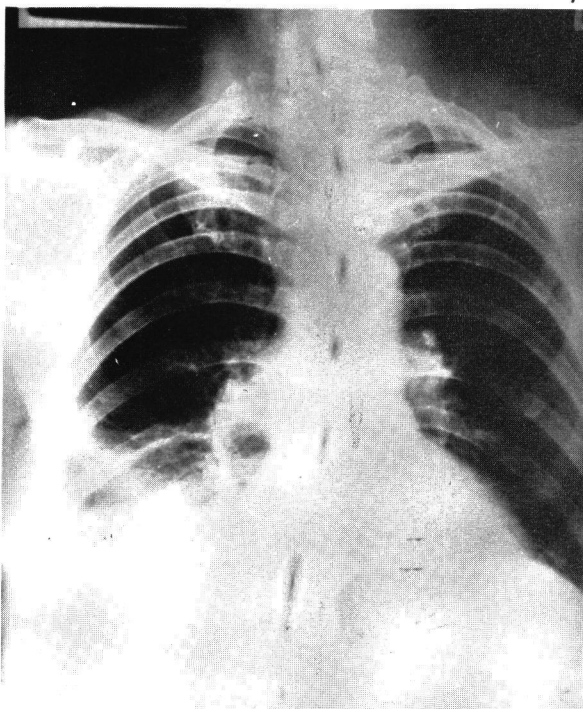


Fig. 1: Chest X-ray showing a right-sided pleural effusion.

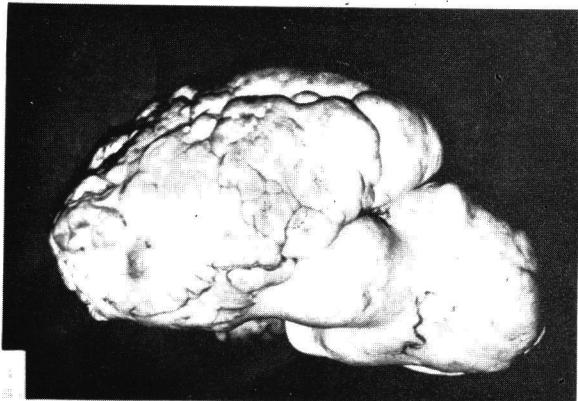


Fig. 2: Photograph of the external surface of the ovarian fibroma.

to cases with the following features: (i) benign solid ovarian tumours such as ovarian fibroma, thecoma, granulosa cell tumour and Brenner tumour; (ii) ascites; (iii) hydrothorax; and (iv) cure after removal of the tumour with complete disappearance of ascites and hydrothorax. In this group, ovarian fibroma is the commonest lesion seen. Meigs⁹ mentioned that of the 84 cases collected in the literature, 69 were pure fibromas, eight thecomas, five granulosa cell tumours and one Brenner tumour. It is to be remembered, however, that ovarian fibroma constitutes only 2% to 5% (Dockerty)³ of all surgically removed ovarian tumours, and that less than 5% (Green)⁴ of all ovarian fibromas give rise to the classical features of Meigs' syndrome. Hence the rarity of this condition.

Meigs' syndrome is seen mostly in menopausal women, the average age being 48 years. The youngest patient reported was a 9-year-old girl, who had a feminising ovarian tumour, weighing 99 grams (Knaus et al).⁷ The average diameter of 312 fibromas of the

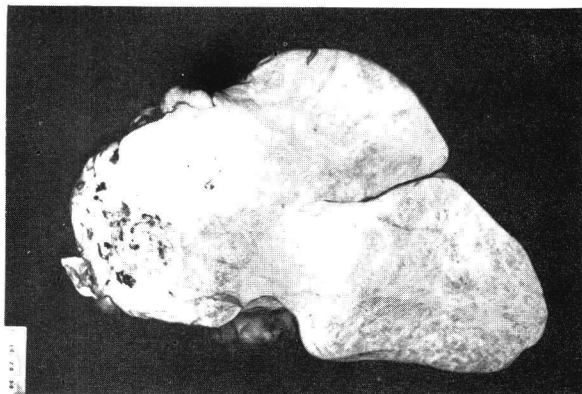


Fig. 3: Cut surface of ovarian fibroma. Note the whorled fibrous pattern and foci of necrosis and haemorrhage (right hand corner).

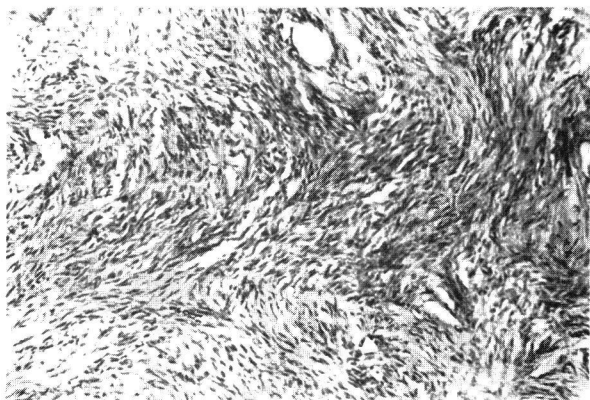


Fig. 4: Photomicrograph of fibroma of ovary showing bundles of well-differentiated collagenous tissue (x 140).

ovary removed surgically from 280 patients (Dockerty)³ was 6 cm; only 14 were larger than 20 cm in diameter. Very few attained a weight of 2,500 grams. Simon¹⁴ reported a case of Meigs' syndrome with an ovarian fibroma weighing 5,200 grams and measuring 26 cm x 23 cm x 7 cm.

True Meigs' syndrome should never include conditions with ascites and hydrothorax secondary to metastases from ovarian or abdominal cancer. It is important that one is clear about the benignity of true Meigs' syndrome, which differs vastly from the fatal outcome in patients with malignant ovarian or other abdominal tumours. In any patient with a pelvic tumour associated with fluid in the abdomen and chest, the possibility of Meigs' syndrome should be considered. If the diagnosis is in doubt, a laparotomy must be performed.

(2) **Pseudo-Meigs' syndrome**⁴ includes other benign pelvic tumours associated with ascites and hydrothorax such as ovarian cysts, teratomas, uterine myomas and papilloma of the Fallopian tube.

(3) **Acute Meigs' syndrome**^{6,12} arises as a result of hyperstimulation of the ovaries by either clomiphene citrate or human menopausal gonadotropin, used for the purpose of inducing ovulation. The condition is characterised by rapid cystic ovarian enlargement, ascites, hydrothorax and occasionally haemorrhage, necrosis and rupture of the cystic ovaries. Janovski⁶ described a case of Acute Meigs' syndrome produced by giving 100 mgm clomiphene daily for 14 days. Vande Wiele¹⁶ similarly had five cases of severe hyperstimulation out of 20 patients treated with human menopausal gonadotropin.

The mechanism of fluid production in Meigs' syndrome remains obscure.

Ascites: Of the numerous theories suggested, three are considered likely. (1) Fluid formation is thought to be secondary to local peritoneal irritation by the tumour. However, this does not explain why ascites is so seldom seen with ovarian cysts or uterine myoma. (2) Direct leakage of fluid from the usually oedematous tumour surface. It is conceivable that obstruction of lymphatics or blood vessels may take place in the tumour itself. (3) Torsion. In most cases there is no torsion. However, partial twisting of the venous return in the pedicle, thereby bringing about an increased transudation from the veins.

Hydrothorax: There is good evidence that hydro-

thorax is the result of upward passage of ascitic fluid into the chest. It is known, for instance, that when the tumour is removed, the ascites and hydrothorax disappear. Radioactive gold administered intra-peritoneally has been recovered from the thorax in cases of Meigs' syndrome.¹⁵ What is more difficult to understand is the actual route by which ascitic fluid passes into the chest. Using carbon particles, Meigs¹¹ has shown that the transfer is not by way of the general circulation. He believes that the most likely pathway is by lymphatic drainage via communicating channels, connecting the subdiaphragmatic and supra-diaphragmatic lymphatics.

Summary

1. A 66-year-old woman with classical Meigs' syndrome, the first recorded case in Malaysia, is described.
2. The literature is reviewed, and a classification of the Meigs' syndrome is discussed.
3. The mechanism of fluid production in Meigs' syndrome is discussed.

Acknowledgements

My thanks are due to Professor D. Chan, Head, Department of Obstetrics & Gynaecology, University of Malaya, for permission to publish this case, and to Dr. T.A. Sinnathuray, Senior Lecturer in Obstetrics & Gynaecology, for helpful advice.

References

1. Blair, R.G. *J. Obstet. Gynae. Brit. Cwlth.*, 68:1046, 1961.
2. Brenner, W.E. and Scott, R.B., *Obstet. & Gynaec.* 31:40, 1968.
3. Dockerty, M.B. and Masson, J.C., *Am. J. Obstet. Gynec.* 47:741, 1944.
4. Green, T.H.: *Gynecology*, ed. 1965. Little, Brown & Co., Boston. p.346.
5. Hammouda, A.A., *Brit. Med. J.* 1:414, 1967.
6. Janovski, N.A., and Southam. *JAMA.* 181:443, 1962.
7. Knaus, W.E. et al. *J. of Pediatrics.* 43:88, 1953.
8. Meigs, J.V. and Cass, J.W. *Am. J. Obstet. Gynec.* 33:244, 1937.
9. Meigs, J.V. *Am. J. Obstet. & Gynec.* 3:471, 1954.
10. Meigs, J.V. *Obstet. & Gynec.* 3:471, 1954.
11. Meigs, J.V., Armstrong, S.H. and Hamilton, H.H. *Am. J. Obstet. Gynec.* 46:19, 1943.
12. Neuwirth, R.S. et al. *Am. J. Obstet. Gynec.* 91:977, 1965.
13. Pankajam, P. and Mehrothra, P. *J. Obst. Gynae of India*, XIX: 521, 1969.
14. Simon, H.J. *Am. J. Obstet. Gynec.*, 53:1042, 1947.
15. Uyttenbroeck, F. Some topical problems in obstetrics and gynaecology. Imprimerie de Bievre, Antwerp, 1961. p. 78.
16. Vande Wiele, R.L. and Turksoy, R.M. *J. clin. Endocr. Metab.*: 25:369, 1965.