

Sarcoidosis among Chinese in Malaysia:

with a report of 10 cases

by *A. K. Dutt*

M.B.B.S. (Calcutta)
Institute for Medical Research,
Kuala Lumpur, Malaysia.

Introduction

IT SEEMS from the study of voluminous literature on sarcoidosis that the condition is less common in Asians than Europeans and white Americans. Ten cases of sarcoidosis are reported here. Most of them occurred in mediastinal and peripheral lymph nodes. One case was associated with leprosy, one with facial paralysis and one with arthritis. Sarcoidosis is extremely rare in the Chinese race as evidenced by the report of only 3 cases in the literature to date. We could not find a single case of sarcoidosis among Chinese in Malaysia and Singapore from the exhaustive search of literature. This paper draws attention to the fact that, of 10 cases of sarcoidosis, 3 occurred in Chinese.

Hutchison (1898), Besnier (1889) and Boeck (1899), as quoted by Mayock et al (1963), were credited with earlier descriptions of sarcoidosis. Sarcoidosis is a multisystem disease of world-wide distribution. The cause of the condition is obscure. Terris and Chaves (1966) failed to demonstrate association of sarcoidosis with tuberculosis and pine pollen after analysing 240 histologically — confirmed cases. James (1967) postulated that hyporeactivity of immunologically — competent lymphocytes to various antigens might produce sarcoid granuloma in the body. Ten histologically — confirmed cases of

sarcoidosis are reported here.

Brief report of cases

Case I: 59-year-old Chinese woman had cervical lymphadenopathy since birth. Biopsy of lymph node showed sarcoid granuloma. (Fig. 1, 2 & 3)

Case II: 21-year-Chinese male was seen with cervical lymphadenopathy of 3 years' duration. Biopsy of lymph node showed sarcoid granuloma. (Fig. 4 & 5)

Case III: 29-year-old Malay male was asymptomatic. On routine roentgenogram of chest, mediastinal lymphadenopathy was found. Biopsy of lymph node showed sarcoid granuloma.

Case IV: Routine X-ray of chest of an Indian woman, aged 16 years, revealed mediastinal lymphadenopathy. Biopsy of lymph node showed sarcoid granuloma.

Case V: A 28-year-old Malay woman presented recurrent polyarthritis of 2 years' duration. Subsequently, she developed nodular skin eruptions, mediastinal and cervical lymphadenopathy. Biopsy of skin nodule showed sarcoid granuloma.

Case VI: 33-year-old Indian woman developed cervical and axillary lymphadenopathy. Chest X-ray was normal. Biopsy of lymph node showed sarcoid granuloma.

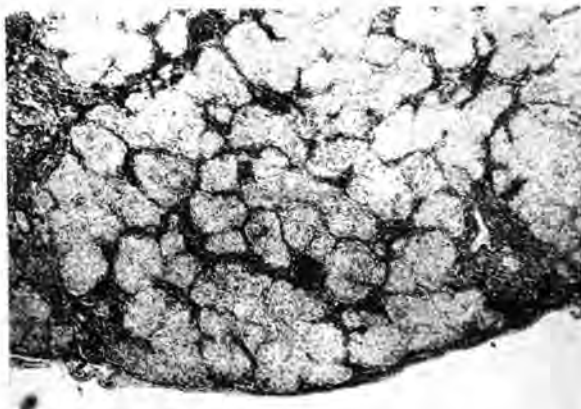


Fig. 1: Extensive uniform sarcoid granuloma of lymph node (hematoxylin and eosin x 65).

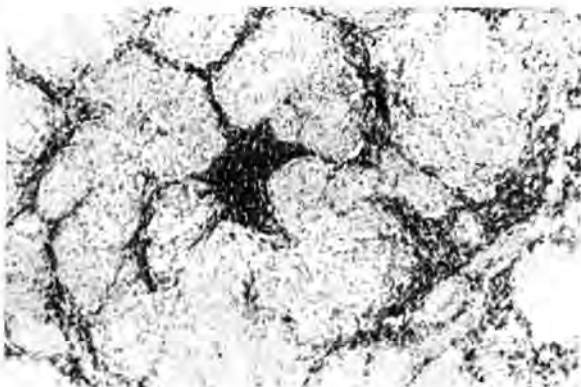


Fig. 2: A group of coalescent sarcoid granulomas of lymph node (hematoxylin and eosin x 160).



Fig. 3: Few foreign bodies and Langhan's type of giant cells in sarcoid granuloma of lymph node (hematoxylin and eosin x 160).

Case VII: Malay male, aged 17 years, had cervical lymphadenopathy and left facial nerve paralysis. Biopsy of lymph node showed sarcoid granuloma.

Case VIII: 13-year-old Indian girl was seen with cervical lymphadenopathy of 6 years' duration. Biopsy showed sarcoid granuloma.

Case IX: 15-year-old Indian male presented cervical lymphadenopathy of 2 months' duration. Biopsy of lymph node showed sarcoid granuloma.

Case X: 25-year-old Chinese woman, who had lepromatous leprosy, was on sulphone therapy for a long time. Recently she developed bilateral inguinal lymphadenopathy. Biopsy of lymph node showed sarcoid granuloma. Kveim test was positive. (Fig. 6)

Discussion

Siltzbach (1965) reported that the highest prevalence rate of sarcoidosis is among the Swedish and lowest among Indians and Eskimos of Canada, and Chinese with high incidence of tuberculosis among the latter three races. Sarcoidosis among the Chinese is extremely rare. Hsing et al (1964) had not found a single case of sarcoidosis among Chinese after reviewing M.M.R. survey of 3.5 million Chinese people in Taiwan during a period of 10 years. Present and Siltzbach (1967) recognized 3 cases of sarcoidosis among the Chinese after exhaustive search of literature. However, they were unable to record a single case of sarcoidosis from the study of M.M.R. survey of 0.6 million Chinese in Singapore. It is interesting to note that we recognized 3 cases of sarcoidosis among Chinese during 4-year survey of 25,000 biopsies at the Institute for Medical Research, Kuala Lumpur. The disease usually occurs in second and third decade of life, both sexes being equally affected. Clinically, sarcoidosis may be classified into 3 types: (I) mildest and most frequent which is characterized by mediastinal lymphadenopathy, erythema nodosum, lung mottlings with 2 years' course; (II) manifested with lung mottlings, extra-thoracic lesions with 2-7 years' course, often followed by healing with residual scarring; and (III) exhibited by generalized lesions with chronic intractable course followed by 10% mortality.

According to James and Sharma (1967), sites of lesion of sarcoidosis in order of frequency are as follows: intrathoracic 84%, eye 27%, erythema nodosum 31%, other skin lesions 25%, spleen 12%, nervous system 7%, parotid 6% and bone 6%. Mayock, in his series of 1,254 cases, found peripheral lymphadenopathy in 76% of cases which fairly correspond to our finding. Occasionally, cases may be associated with

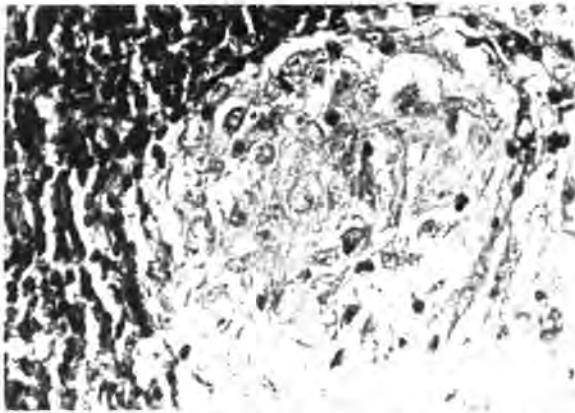


Fig. 4: An epithelioid cell granuloma of sarcoid of lymph node. Note absence of caseative necrosis (hematoxylin and eosin x 1025).

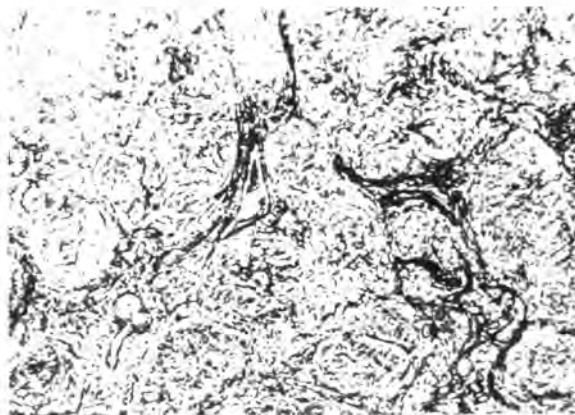


Fig. 5: Normal architecture of reticulin is maintained in sarcoid granulomas of lymph node (Gordon and Sweete x 160).

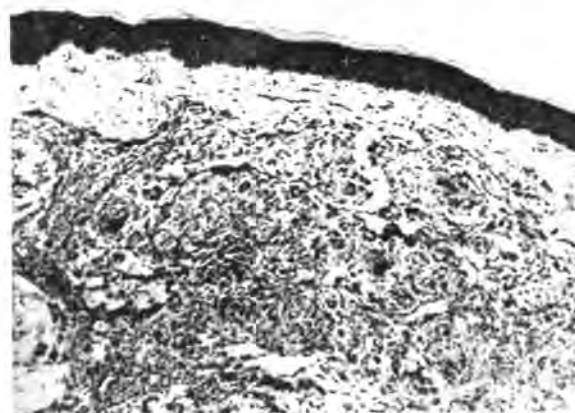


Fig. 6: Strongly positive Kveim test (hematoxylin and eosin x 160).

leprosy, arthritis and facial paralysis (Ramachandran, 1963; Mayock et al 1963). Israel (1964) observed that in most cases clinical and radiological features are not diagnostic; diagnosis is confirmed by Kveim test or biopsy.

According to International Conference of Sarcoidosis, as quoted by Kitamura et al (1967), criteria for diagnosis of sarcoidosis are classified into 4 groups; group I, both biopsy and Kveim test are positive; group II, biopsy negative or omitted but Kveim test positive; group III, biopsy positive but Kveim test negative or omitted; and group IV, both biopsy and Kveim test negative. Diagnosis of four cases was made on the basis of group III classification. Kveim test was performed in only one case. Incidence rate of tuberculin-negative cases is variable; as for instance 86% in the series of 419 cases of Maycock et al (1963) and 52% of 219 cases studied by Kitamura et al (1967).

Histologically, the lesion of lymph node, as observed by Williams (1967) is characterized by extensive uniform multiple granuloma replacing almost whole structure. There is focal infiltration of epithelioid cells without or with Langhan's or foreign body giant cells surrounded by scanty lymphocytes; central caseative necrosis is strikingly absent. Normal reticulin structure is maintained. 50–75% intrathoracic lesions, as quoted by Reisner (1967), regress spontaneously; 15–20% of cases is progressive causing irreversible organic changes with chronic disability.

Corticosteroid is the treatment of choice for the lesions of eye, disfiguring skin lesions, persistent hypercalcemia, progressive pulmonary lesion and myocardial sarcoidosis (Israel, 1964).

Summary

10 cases of sarcoidosis involving mediastinal and peripheral lymph nodes, of which 3 occurred in Chinese, are reported. Literature on sarcoidosis is reviewed with special reference to the incidence of the condition among Chinese.

References

- Hsing, C.T., Han, F.C., Liu, H.C. and Chu., B.Y. (1964). Sarcoidosis among the Chinese. *Amer. Rev. Resp. Dis.*, 89:917–912.
- Israel, H.L. (1964). Sarcoidosis. *Postgraduate Med.*, 36:493–497
- James, D.G. and Sharma, O.P. (1967). Extrathoracic sarcoidosis. *Proc. Roy. Soc. Med.*, 60:992–994

- James, D.G. (1967). Clinical aspects of sarcoidosis. *Hospital Medicine*, 2:8-13
- Kitamura, K., Shigematsu, I. and Hosoda, Y. (1967). Sarcoidosis in Japan. Observations on 700 cases. *Amer. Rev. Resp. Dis.*, 96:952-956
- Leading article (1967). Arthritis and sarcoidosis. *B.M.J.*, 4:568-569
- Mayock, R.L., Bertrand, P., Morrison, C.E. and Scott, J.H. (1963). Manifestations of sarcoidosis. Analysis of 145 patients with a review of nine series selected from the literature. *Amer. J. Med.*, 35:67-89
- Present, D.H. and Siltzbach L.E. (1967). Sarcoidosis among the Chinese and a review of the world-wide epidemiology of sarcoidosis. *Amer. Rev. Resp. Dis.*, 95:285
- Ramachandran, N. (1963). Sarcoidosis with leprosy. *J. Ind. Med. Assoc.*, 40:170-172
- Reisner, D. (1967). Observations on the course and prognosis of sarcoidosis. *Amer. Rev. Resp. Dis.*, 96:361-380
- Siltzbach, L.E. (1965). Current thoughts on the epidemiology and etiology of sarcoidosis. *Amer. J. Med.*, 39:361-368
- Snelling, M.R. and Chooi, M.K. (1966). Pulmonary sarcoidosis. *Singapore Med. Journ.*, 7:240-243
- Terris, M. and Chaves, A.D. (1966). An epidemiologic study of sarcoidosis. *Amer. Rev. Resp. Dis.*, 94:50-55
- Williams, W.J. (1967). The pathology of sarcoidosis. *Hospital Medicine*, 2:21-27.