

Pyloric obstruction due to formic acid ingestion

by J. Lambeth and K. Somasundaram

MD

FRCS

Faculty of Medicine,
University of Malaya.

Introduction

MODERN TECHNOLOGY requires extensive use of corrosives, thereby increasing the likelihood for medical accidents with these substances. Knowledge of the nature of injury caused by the different corrosives is obviously important. Thus forearmed, the physician or surgeon can determine the proper treatment without delay.

A recent instance of accidental ingestion of formic acid allowed us to document the development of pyloric obstruction from an unusually early stage. Formic acid is commonly employed to convert tree latex into a coagulum for processing into sheets. Planned surgical therapy permitted return of the patient to useful employment without excessive morbidity.

Case Report

A 21-year-old male rubber tapper accidentally drank a cup of formic acid on 7/1/69. Immediate oral, retrosternal, and epigastric burning occurred, but abated over the next two days with antacid

therapy. Examination one day post-ingestion revealed only injection of the pharynx.

Seven days after ingestion of the corrosive substance, a barium meal examination demonstrated marked mucosal irregularity and moderate narrowing of the gastric antrum (Figure 1). At this time, the patient denied symptoms and ate solids without difficulty. A second barium meal performed 28 days after ingestion showed severe narrowing of the antrum, complete absence of mucosal folds in the antrum, and sharp demarcation of the narrowed antrum from the body of the stomach (Figure 2). The oesophagus appeared normal at both examinations. About this time, the patient began vomiting all solids. Eight days later, he underwent a Bilroth I partial gastrectomy. After an uneventful recovery, the patient was discharged on the eighth post-operative day.

Examination of the resected specimen (Figure 3) revealed circumferential superficial ulceration of the entire antrum. Inflammatory cells infiltrated the muscular wall, but significant fibrosis had not occurred.

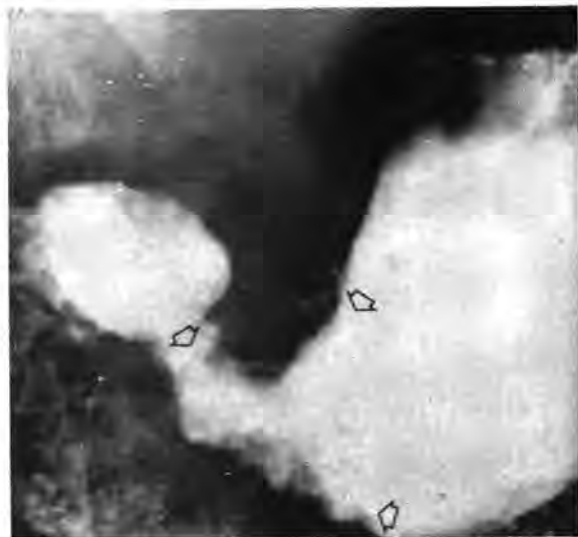


Fig 1: Barium meal 7 days after ingestion of acid corrosive shows (arrows) mucosal irregularity and diffuse narrowing of the gastric antrum.

Discussion

Acid corrosives preferentially affect the distal stomach and produce a progressive stenosis. Pyloric obstruction has been reported after swallowing hydrochloric acid, sulfuric acid, nitric acid, acetic acid, trichloroacetic acid, carbolic acid, oxalic acid, lye and lysol, ferrous sulfate, copper sulfate, bichloride of mercury, formaldehyde, clorox, zinc chloride, ammonium hydroxide, tincture of iodine, and chlorine (Poteshman, 1967). Hydrochloric acid is the agent most frequently incriminated in cases of stenosis while sulfuric acid is most likely to cause early death due to perforation and gangrene.

Only one-fifth of patients with pyloric stenosis due to acid ingestion develop an associated oesophageal stricture (Gray and Holmes, 1948). Alkaline corrosives have a more marked effect on the oesophagus, but occasionally also cause pyloric obstruction. These substances are usually more concentrated and corrosive than acids and therefore are more injurious to the resistant oesophageal squamous epithelium. The normal gastric acidity partially neutralizes the base with relative sparing of the gastric mucosa.

The selective damage by acid on the distal stomach is related to its rapid passage down the oesophagus and along the lesser curvature. The normal alkalinity of the pharyngeal and oesophageal mucosa tends to neutralize weak acids. However, when the corrosive reaches the antrum and pylorus, tetanic contractions

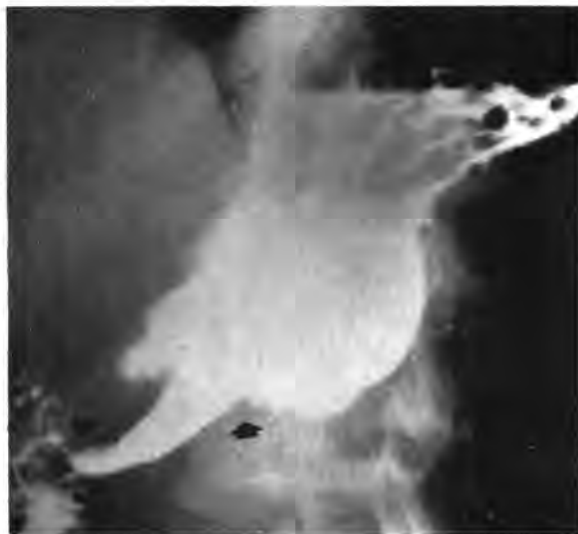

Fig. 2: Barium meal 28 days after acute injury shows the stenosis and complete absence of mucosal folds in the antrum (arrows).

are set up as experimentally demonstrated by Testa (Schulenberg, 1941). Contact is thus prolonged, resulting in severe injury to the sensitive gastric columnar epithelium. Poteshman (1967) and Nevin, Turner, and Gardener (1959) were able to show radiologic changes in the gastric mucosa as early as nine days after insult. The initial effect on the stomach is swelling of the mucosal folds. Then, depending upon the nature and strength of the caustic agent, inflammatory reaction sets in, followed by necrosis of the affected mucosal or submucosal layers. At this stage, large irregular gastric ulcerations may be present. Subsequent action of the gastric acid upon the denuded surface gradually leads to a chronic inflammatory process, ending in a severe scarring or stenosis. Our case illustrates this predictable course.

Initial treatment obviously consists of intensive antacid therapy. In spite of this, inflammatory thickening of the pyloric and antral wall occurs quite soon after initial injury and surgery for relief of obstruction is eventually required in almost all cases (Marks and colleagues, 1963). Non-operative measures for the treatment of obstruction in the hope of avoiding surgery have not often been successful and may increase the morbidity.

Early surgery, within the first two weeks after corrosive injury, may be hazardous because of friability and edema of the gastric wall. Marks and colleagues (1963) have found that a feeding jejunos-

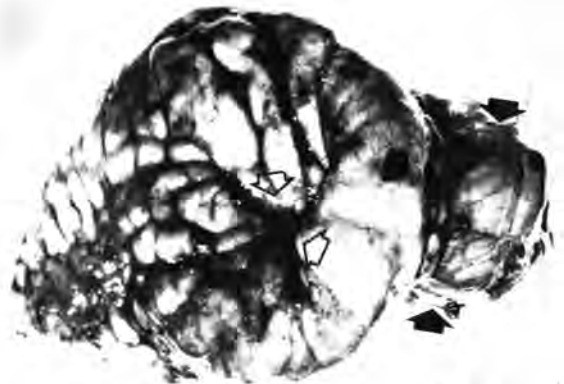
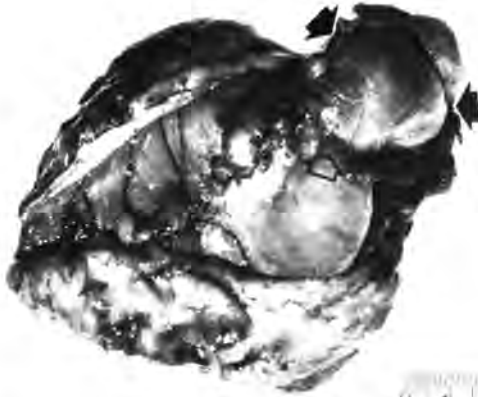

Fig. 3 and 4: The resected distal stomach is viewed from the greater curvature side (Fig. 3) and the lesser curvature side (Fig. 4). Arrows outline the stenotic segment.

greater curvature side (Fig. 3) and the lesser curvature side

tomy is often helpful in this acute phase. Subsequent operative relief of obstruction may either be by gastroenterostomy or limited gastrectomy. Cohen (1967) has advocated a posterior gastroenterostomy because of the danger of leaks at anastomotic sites after gastrectomy. A limited gastrectomy was done in the case presented without aid of a previous jejunostomy and no difficulties were encountered.

Summary

A case presentation illustrates the occurrence of severe gastritis and rapid development of antral obstruction following ingestion of acid corrosive. Radiographs show early mucosal inflammatory changes which progress to stenosis. Emphasis is placed upon the frequent necessity for eventual operative relief of the stenosis.

Acknowledgements

The authors are indebted to the Department of Medical Illustration, Faculty of Medicine, University of Malaya, for the photographs and to Miss Elsie Tan for her assistance in preparing this paper.

References

- Cohen, D. (1967) *Aust. New Zea. J. Surg.*, 37: 70-72.
- Gray, H.K. and Holmes, C.L. (1948). *Surg. Clin. North America*, 28: 1041-1056.
- Marks, I.N., Banks, S., Werbeloff, L. Farman, J., Louw, J.H. (1963). *Amer. J. Digest. Dis.*, 8: 509-524.
- Neven, I.N., Turner, W.W., Gardener, H.T. (1959). *Amer. J. Roent.*, 81: 603-608.
- Poteshman, N.L. (1967). *Amer. J. Roent.*, 99: 182-185.
- Schulenberg, C.A.R. (1941). *Lancet*, 2: 367-368.