

**NOTES ON A CASE OF COINCIDENT INTRA-UTERINE AND  
EXTRA-UTERINE GESTATION**

BY

K. K. MANDAL, M.B.B.S. AND S. K. MITRA, M.B.B.S.  
*of District Hospital, Klang, Malaya*

A patient, Yew Peck Toh, female Chinese, 34 years old, was admitted into the District Hospital, Klang, on 18.7.1960, being referred by a private Medical Practitioner, Dr. Chong Soon Fong, with complaints of bleeding per vaginam, and lower abdominal pain since the morning of the 18th July, 1960.

*Following are the history and findings:—*

Patient has been married for five years.

Menstrual history — regular (20–30 days cycle).

Past obstetric history — Gravida — 3. Para 2.

Abortion — 1 (2 months in February, 1960 — spontaneous and uneventful).

Age of last child — 3 years.

L.M.P. May 1960.

History of twins in family or self — NIL.

History of leucorrhoea — NIL.

Past history of V.D. — NIL.

*On Examination*

General condition: Slightly anaemic. Nutrition — good.

Pulse: 94 p.m.

Respiration: 22 p.m.

Temperature: 99.4 F.

B.P. : 124 m.m. of Hg.

88

*Abdomen* Tenderness on deep palpation on lower abdomen.  
No rigidity or muscle guard.

*P.V. Examination*

Outlet — Lax.

Vagina — Pale.

Cervix — External Os — admits just tip of index  
finger.

Internal Os — closed.

Soft in feel.

Central in position.

Uterus — Size of ten weeks.

Culs — Right — clear,

Left — slight tender resistance felt.

Examination of other systems: N. A. D.

*Diagnosis:* Threatened abortion.

*Treatment:* Rest in bed.

Inj. Proc. Penicillin 300,000 units b.d.

Mist. Pot. Bromide 0z I t.d.s.

*Day to day follow up*

19. 7. 60 Temp. settled down to normal.

Pulse came down to 84 p.m.

B.P. 124 m.m. of Hg.

88

No bleeding p.v.

No complaints.

20. 7. 60

Condition same.

Patient looks better.

Pulse — 84 p.m. B.P. 120 m.m. of Hg.

88

21. 7. 60

No complaints.

Patient looks fit.

Discharged from hospital with advice, for rest in bed and Phenobarb Tab. Gr.  $\frac{1}{2}$  b.d. for one week.

On 21st July, 1960 patient came back with a letter from another Medical Practitioner, Dr. Lim Sian Lok, suspecting Ectopic pregnancy. Patient was immediately admitted into the hospital. She complained of severe abdominal pain and bleeding per vaginam, since the night of 20th instant.

*On Examination* General condition: shocked and anaemic. Pallor +

Pulse 104 p.m.

B.P. 120 m.m. of Hg.

70

Temp. 99°F.

Abdomen: Extremely tender especially over the lower abdomen.

Rigidity of lower abdomen +

Rebound tenderness of lower abdomen +

Height of fundus not felt.

*P.V. Examination*

Outlet — Lax.

Vagina — Pale.

Os — Internal Os admits Index finger. Product of conception felt.

Soft in feel.

Extremely tender.

Uterus — Size of ten weeks.

Retroverted and retroflexed.

Appears flattened antero-posteriorly.

Culs — Left tubo-ovarian mass felt which was tender also.

Right — clear.

Pouch of Douglas — slight bulging felt, soft in feel and tender.

*Examination of  
breasts*

Veins are dilated on the surface of skin with slight clear secretion on expression of breasts.

*Other systems:* N. A. D.

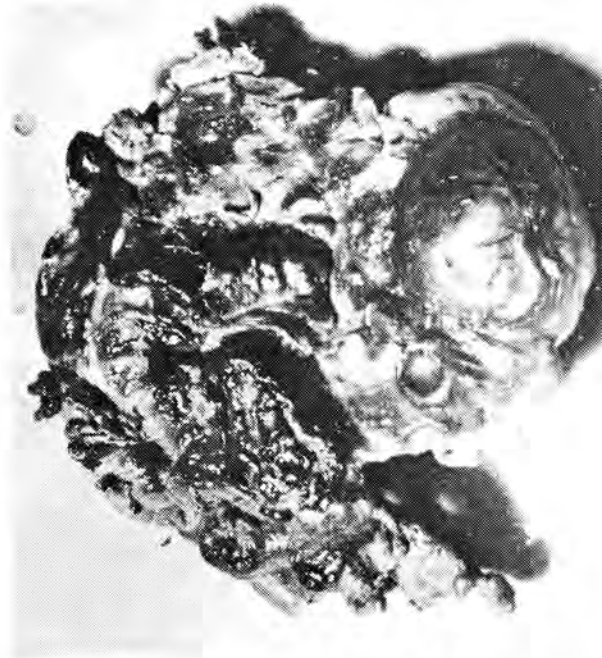
*Laboratory Examinations*

Total white count:	10,800 c.m.m.
Differ. count:	Poly — 80%
	Lympho — 18%
	Mono — 1%
	Eosino — 1%
Hb.	65%
Blood group	"O"

*Provisional Diagnosis:* Ruptured Ectopic gestation with ? Intra-uterine pregnancy threatening abortion.

*Treatment decided  
upon:*

*Laparotomy:* Laparotomy was performed under spinal anaesthesia (*Cinchocaine* 4 c.c.). On opening peritoneum, dark altered blood and blood clots were found in lower abdomen especially on the left side of pelvic cavity and pouch of Douglas.

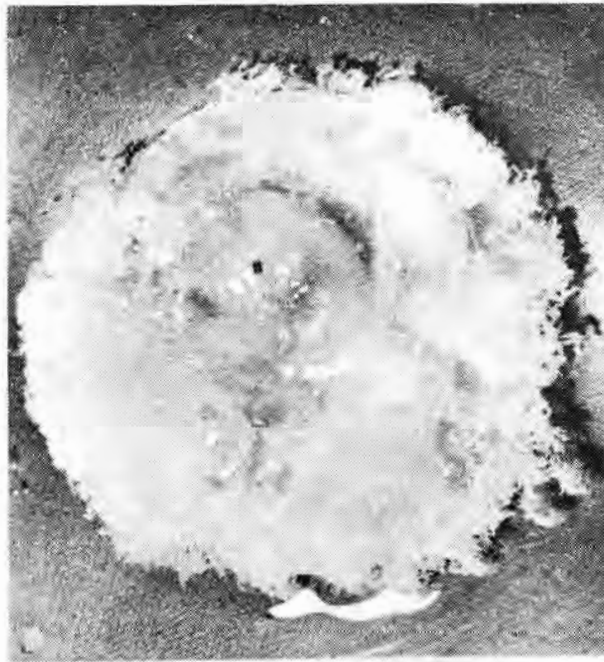

PHOTOGRAPH NO I

L. Tubo-ovarian Mass.

A left tubo-ovarian mass adherent to the left ovary and pelvic colon was seen. The tubo-ovarian mass was dissected out, clamped and removed along with the left ovary. A big raw area was seen in pouch of Douglas after removal of the tubo-ovarian mass and the blood clots, suggesting the invasion of the pouch of Douglas by the chorionic villi.

The uterus was found to be retroflexed and retroverted, and enlarged of ten weeks size. It was flattened antero-posteriorly, and soft and flabby in feel. Hysterotomy was decided upon as the signs and symptoms of inevitable abortion were apparent. Products of conception were removed and a foetus of ten weeks size in an intact amniotic sac was found. Uterus was sutured in layers.



**PHOTOGRAPH NO II**

Foetus from Uterus.

Naked eye examination of the isthmus of left Fallopian tube showed no sign of old inflammation or stenosis. Right Fallopian tube and right ovary were found to be normal. Other abdominal viscera were normal.

Abdomen closed in layers with rubber tube drainage as there was oozing of blood from the raw area in the Pouch of Douglas.

#### *Post Operative Treatment*

Blood transfusion, Inj. Achromycin 500 mgm I.V. to start with and then 250 mgm six hourly, Inj. Largactil and Inj. Morphia when necessary.

Post operative recovery and convalescence were uneventful.

*Discussion*

The patient was first admitted on 18th July, 1960 with the signs and symptoms of threatened abortion. She responded to treatment and rest, and was discharged from hospital after a few days as the vaginal bleeding and pain in the lower abdomen subsided. There was no suspicion of Ectopic pregnancy at that time.

On the 21st July, 1960 patient came back with signs and symptoms of Ruptured Ectopic pregnancy. Pain in the lower abdomen was severe with some bleeding per vagina. It was confusing at first to find a gravid uterus at the same time with signs of inevitable abortion. However there was no doubt that there was haemorrhage in the lower abdomen due to a ruptured Ectopic. Laparotomy was decided upon and it was confirmed that there was a ruptured tubal pregnancy on the left side. From the nature of the blood it was found that the rupture might have taken slowly for the past few days.

Implantation of the ovum was upon the fimbriae and the ovary was firmly adherent to the mass as shown in the photograph No. 1.

Hysterotomy was decided upon as the internal Os was dilated one finger (suggesting inevitable abortion). The uterus was bulkier than it should have been in a normal ruptured Ectopic pregnancy. Normal globular shape of the uterus was also lost. In view of the past history of vaginal bleeding which was moderately severe and in presence of the signs of inevitable abortion a hysterotomy was done. The foetus in utero of about ten weeks size is shown in photograph No. 2.

The remaining portions which included the isthmus and interstitial parts of left Fallopian tube after removal of the tubo-ovarian mass were found normal. There was no sign of inflammation in the right Fallopian tube, ovary, uterus or pelvic adenexa. Other pelvic and abdominal organs were normal.

To exclude the routine causes of tubal pregnancy, patient's and her husband's blood for Kahn were done and were found to be negative. Past history of septic abortions or puerperal sepsis have been excluded. Patient led a normal and healthy married life before admission to Hospital. Husband gives no history of venereal disease. His prostatic smear for Gonococcus was negative.

So far no record of a case of coincident intra-uterine and extra-uterine gestation has been found in the Medical Journal of Malaya and hence my decision to publish this case.

I take this opportunity to acknowledge my sincere thanks to my colleagues, Dr. S. K. Mitra and Dr. Lim Sian Lok who had encouraged me to write this paper and had taken the trouble of giving me their valuable advice and help. I am also grateful to the Director of Medical Services for his kind permission for publishing this.

*P.S.* — Photograph No. 1 shows the fimbriated end of the left fallopian tube with L. ovary firmly attached to it. The products of conception were mostly dissected out during the operation and are not shown in the photograph.